

Urinary Tract Reconstruction for Continence and Renal Preservation

Curtis A. Sheldon and Eugene Minevich

Recent advances in surgical technique, the successful application of intermittent catheterization to the reconstructed urinary tract, and the lessons learned from the pioneering work on urinary undiversion allow even the most anatomically devastated children to be reconstructed for continence as well as preservation of renal function. Such reconstructive principles may now be applied to virtually all urinary tract anomalies with a good expectation of success. Reconstructive options are presently available even for those children with end-stage renal disease for whom renal transplantation will ultimately be required.

Owing to the high incidence of upper-tract deterioration with time and the significant sequelae of altered body image following cutaneous urinary diversion, incontinent diversion is no longer considered an acceptable alternative to reconstruction in the pediatric population. Exceptions to this include temporary diversion for stabilization of renal function while awaiting ultimate reconstruction and extenuating circumstances where more formal continent reconstruction is not applicable.

CONCEPTUAL APPROACH TO URINARY TRACT RECONSTRUCTION AND PREOPERATIVE EVALUATION

There are four components to balanced urinary tract function that must be achieved in order to ensure long-term success with urinary reconstruction. The first component is that of adequate bladder (reservoir) capacity and sufficient compliance to provide low-pressure storage. The maintenance of storage pressures below 35 to 40 cm H₂O will optimize upper-tract preservation. Optimal bladder capacity should allow a 4-hour catheterization or voiding interval during the day, and an 8-hour interval at night without reaching excessive pressure or precipitating incontinence.

The second component is that of adequate bladder outlet resistance to maintain urinary continence. Third, there must be a convenient, reliable mechanism for bladder (reservoir) emptying. Ideally, this should be achieved by spontaneous voiding, otherwise intermittent catheterization is necessary. The native urethra may represent an acceptable conduit for this maneuver, although should its catheterization prove excessively difficult or uncomfortable (preventing patient compliance), an alternative catheterizable conduit may be necessary. Fourth, unobstructed and nonrefluxing sterile upper-tract drainage of urine into the bladder (reservoir) is desirable in order to protect the upper tracts.

When contemplating urinary tract reconstruction, meticulous preoperative evaluation is critical. It is essential to tailor the recon-

struction to the individual needs of the patient. Renal function is assessed by measurement of serum creatinine and glomerular filtration rate (including measurement of differential function via radioisotope techniques). Anatomy is assessed by intravenous urography or ultrasound, contrast voiding cystourethrography and careful preoperative endoscopic evaluation. Evaluation of bladder and sphincteric function is of paramount importance. Here, detailed urodynamic investigation, as well as upright cystography to evaluate the competence of the bladder neck, are performed. A careful history, physical examination, and counseling of the patient and family allows an assessment of the patient's intellect, dexterity, and potential for self-care. After this assessment is completed, an exhaustive trial of nonoperative therapy is undertaken. This trial may include the use of pharmacologic agents (anticholinergics, sympathomimetics, or sympatholytics) in an attempt to achieve safe intravesical pressure from the perspectives of upper-tract preservation and continence. This trial of therapy may also include intermittent catheterization, which may result in sufficient stabilization of the urinary tract, thereby avoiding any surgical reconstruction. Moreover, this important therapeutic modality indicates the need for urinary tract reconstruction where spontaneous voiding would be unlikely.

COMPENSATING FOR INADEQUATE BLADDER CAPACITY OR COMPLIANCE

Physiologic Considerations

There are several important reconstructive concepts pertinent to bladder augmentation. The first regards the management of the recipient bladder. If bowel augmentation is performed, leaving the detrusor essentially intact to generate high pressures, then the augmented segment will act urodynamically as a capacious diverticulum. This type of diverticular decompression instead of augmentation can occur if bowel is added to either a neurologically intact or impaired bladder. The problem can be avoided by an extended sagittal opening of the bladder ("clam cystoplasty"). Essentially, this is a reconfiguration of the bladder from a sphere into a flat plate, so that the detrusor is no longer capable of generating a contraction that produces a significant pressure elevation.

Just as pressure generated by the bladder detrusor is an important contributor to the pressure generated in an augmented urinary reservoir, so also is the pressure generated by the bowel segment itself. With peristaltic contractions, pressures ranging from 60 to 100 cm H₂O may be encountered. This observation led Kock to develop his concept of turning the intact bowel into a reservoir

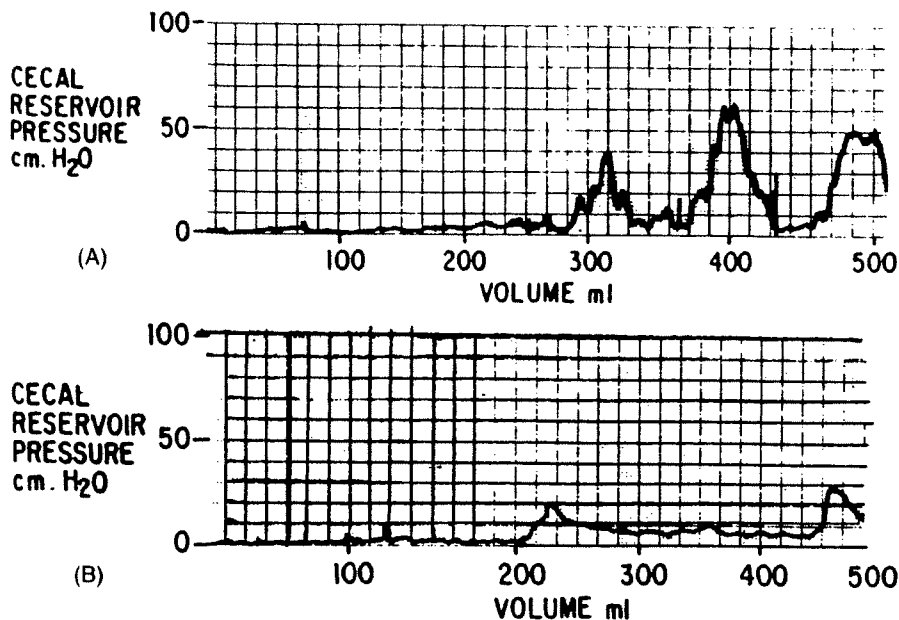


FIGURE 80-1. Urodynamics of cecal reservoir. (A) Tubular bowel produces high-pressure peristaltic waves. (B) Cup patch bowel with peristalsis disrupted stores large volume without pressure rise. (From Goldwasser HR, Webster GD. Augmentation and substitution enterocystoplasty. *J Urol* 1986;135:215. Used with permission.)

incapable of effective peristalsis by creating a "pouch." Opening the bowel along its antimesenteric border and closing it with disruption of the circular muscle ("detubularization") inhibits peristalsis. Once unable to undergo peristalsis, the reservoir dilates and stores urine at a low pressure (Fig. 80-1). Additionally, there is a very significant increase in the geometric capacity of the intestinal segment. A third important concept is that of accommodation (Fig. 80-2). It is well known that the reconstructed bladder will gradually enlarge over time. At a constant pressure, a structure with a larger radius will accommodate a greater volume—again, an advantage of detubularized bowel segments.

Bladder augmentation can be performed with various donor tissues such as ileum, colon, ileocecal region, stomach, and ureter. There are a large variety of continent urinary diversions that have greatly increased the number of patients who are candidates for

continent reconstruction. Such diversion may be either external, involving a variety of segments of the gastrointestinal tract, or internal, such as ureterosigmoidostomy, its multiple variations, and the rectal bladder.

There are several considerations to be entertained when choosing an augmentation donor site. There are anatomic considerations, such as mobility of blood supply, which favor the use of ileum, sigmoid, the ileocecal region, and the greater curvature of the stomach. The ability to implant a ureter or a Mitrofanoff neourethra may also be a consideration. Additionally, it may be important to avoid the peritoneal cavity so as to preserve peritoneal dialysis or a ventricular peritoneal shunt. Such considerations favor the use of ureteral augmentation or autoaugmentation.

The choice of augmentation donor site may be limited by the patient's primary disease. Patients with short gut may not tolerate a loss of the ileocecal region or a significant length of ileum. Patients with borderline fecal continence (such as those with imperforate anus or myelodysplasia) may not tolerate loss of the ileocecal valve or the water reabsorptive capacity of the right colon. Metabolic consequences may assume an overriding influence: the risk of absorptive acidosis and growth retardation, which may be exacerbated by chronic renal insufficiency, may favor the use of autoaugmentation, ureteral augmentation, or gastrocystoplasty techniques.

Because the reconstruction must be tailored to the individual needs of the patient, the surgeon must be familiar with a wide variety of reconstructive alternatives and prepare the patient accordingly. This includes bowel preparation, even when gastrocystoplasty, autoaugmentation, or ureteral augmentation are anticipated.

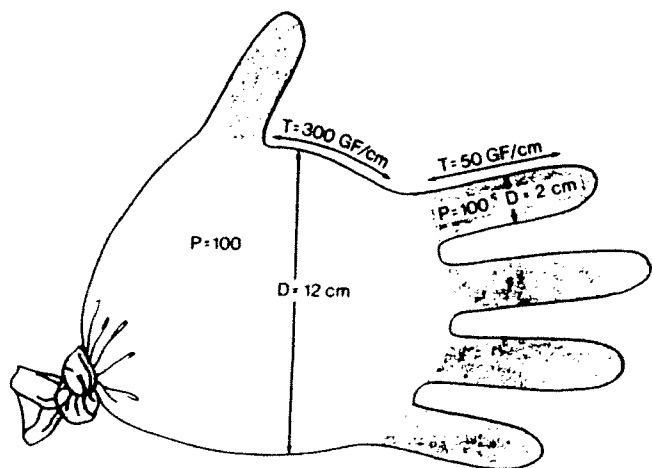


FIGURE 80-2. Inflated surgeon's glove illustrates Laplace's relationship. Although pressure (P) is equal throughout, tension (T) is greater in the portion with greater diameter (D). (From Hinman F. Selection of intestinal segments for bladder substitution: Physical and physiological characteristics. *J Urol* 1988;139:522. Used with permission.)

Small-Bowel Procedures

Ileocystoplasty is the most frequently used augmentation technique. A 20- to 40-cm segment of ileum is selected, such that it will easily reach the bladder. After the segment is resected, detubularized, and reconfigured, it is anastomosed to the bladder using a two-layer closure with running 3-0 Vicryl sutures (inner-layer interlocking) (Fig. 80-3). Voiding in augmented bladders occurs primarily through a pressure rise generated through abdominal straining and

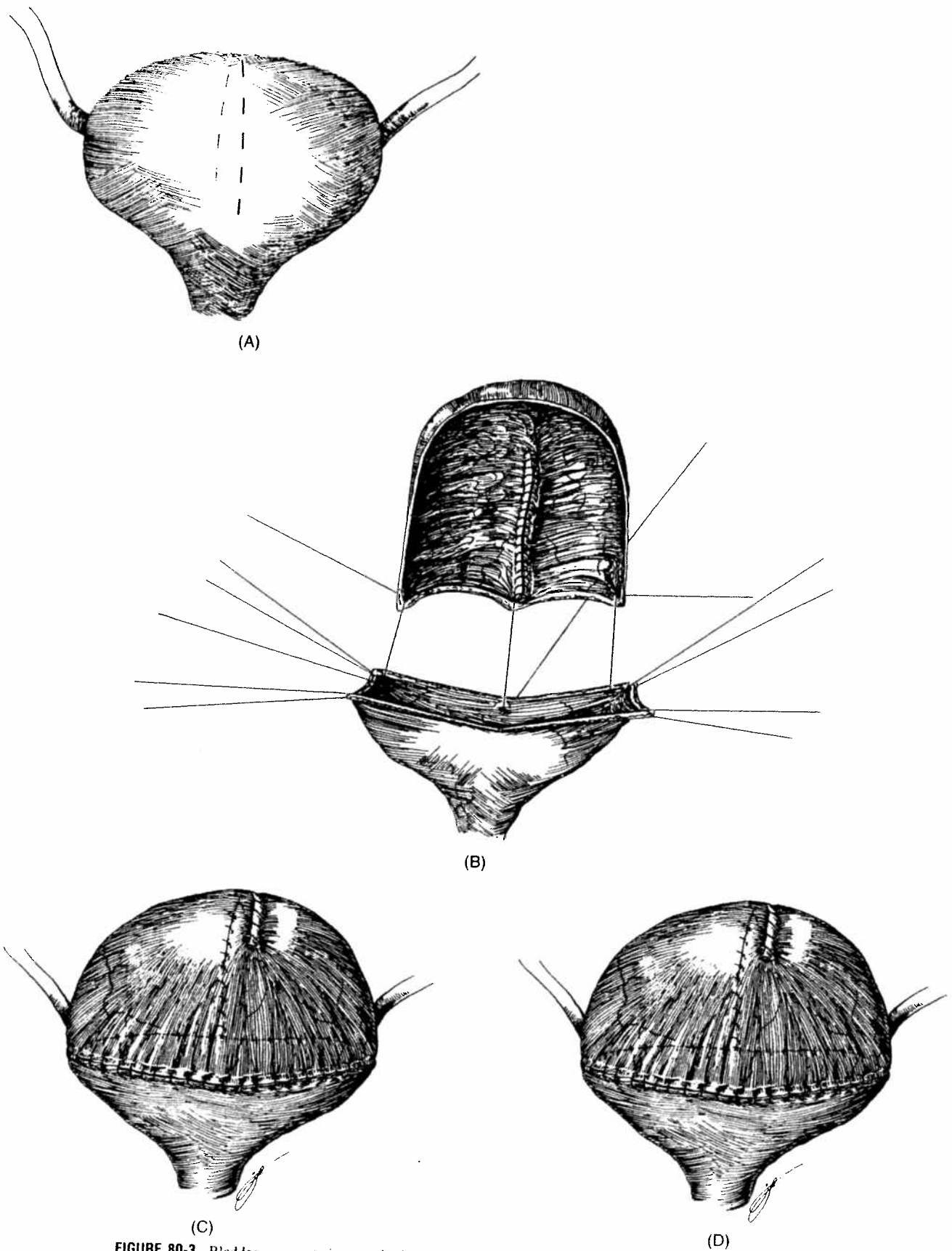


FIGURE 80-3. Bladder augmentation employing an intestinal segment. (A) The bladder is opened as a "clam shell." (B) The intestinal segment is detubularized by longitudinal incision along the antimesenteric border. A cup-patch is fashioned by suturing one edge of the resultant rectangle to itself. (C) The cup-patch is sutured to the remnant bladder plate. (D) Final appearance.

incomplete emptying is common. Intermittent self-catheterization may be required for effective emptying.

Other techniques of bladder augmentation or replacement using small bowel include the Camey procedure (Fig. 80-4), Kock pouch (Fig. 80-5), and ileal neobladder. These procedures are less successful in achieving continence and have a significant rate of complications and reoperation.

Ileocecal Segment Procedures

Urologists favor the ileocecal bowel segment for bladder reconstruction because of the natural configuration of the cecum, which gives it the appearance of an ideal substitute for the bladder. Experience with the native ileocecal valve as an adequate antireflux mechanism, however, has not been encouraging. Consequently, various surgical modifications of the ileocecal valve have been introduced in an effort to try to lessen the incidence of reflux.

When the cecal or ileocecal segment has been used intact for bladder augmentation, nighttime incontinence has been a significant problem in most series. This problem most likely reflects peristaltic waves in the intact bowel segment, because enuresis is rare when the cup patch technique is used. Other continent diversions employing the ileocecal valve include the Maintz pouch, the Penn pouch, the Indiana pouch, and the Florida pouch. Of these tech-

niques, the Indiana pouch has been applied most frequently in pediatric practice and has met with variable results.

Large-Bowel Procedure

Mathisen reported sigmoid augmentation of the bladder by the "open loop" technique in 1955, which is, in essence, the cup-patch technique of Goodwin discussed earlier. This technique did not appear to differ from other bowel segments with respect to ability to empty, infections, electrolyte abnormalities, or other significant variables. Positive experiences with construction of a colonic neobladder have been reported, although nocturnal incontinence remains a problem in up to 33% of patients.

Gastric Segment Procedures

The work of Mitchell and coinvestigators ushered in the modern era of the use of stomach in urinary reconstruction (Fig. 80-6). They demonstrated gastrocystoplasty to be highly successful, versatile, and well tolerated, even in the face of azotemia. Our long-term follow-up with gastrocystoplasty or gastric neobladder reveals a continence rate of 91%, stable renal function in all patients, and upper-tract deterioration in only one patient who became noncompliant with intermittent catheterization.

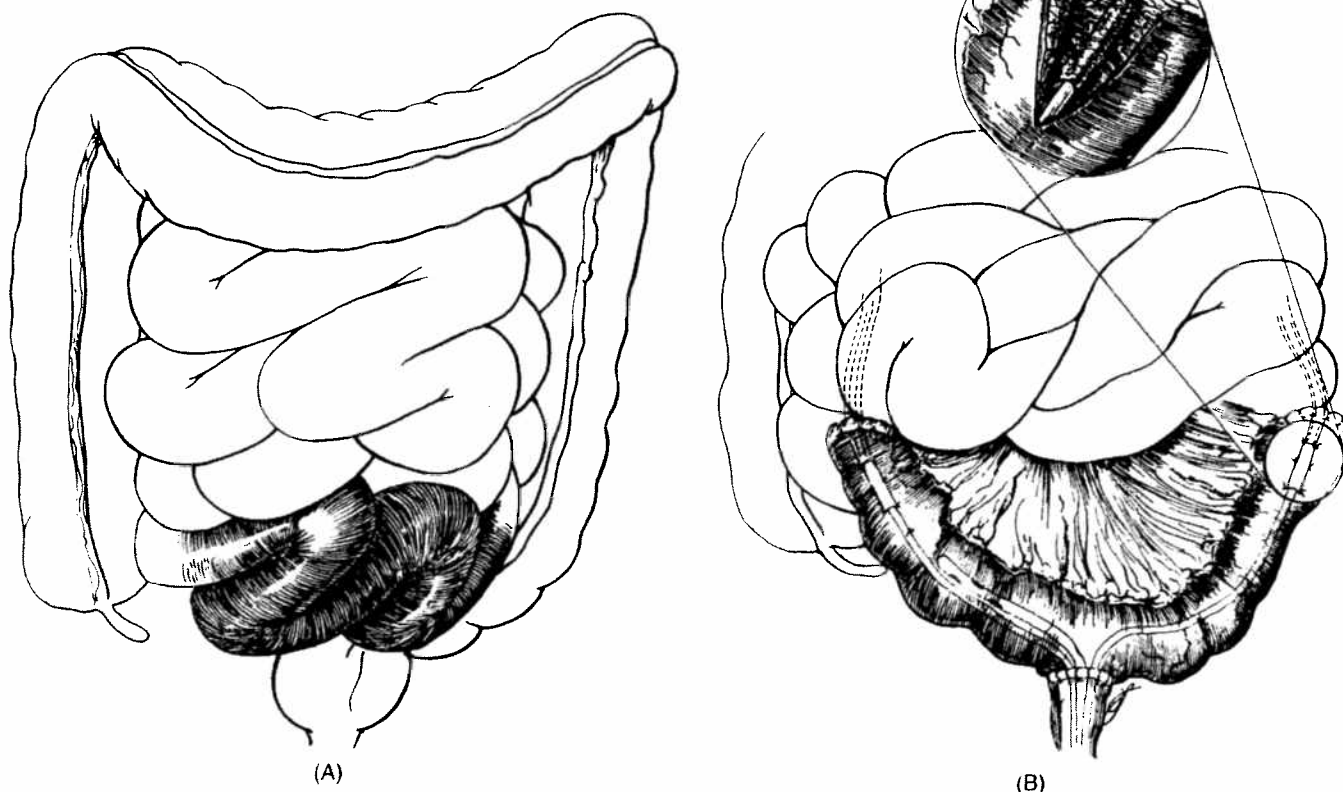


FIGURE 80-4. Camey enterocystoplasty: (A) A 35- to 40-cm length of intact ileum is anastomosed to the urethral stump to create a continent intestinal reservoir. (B) Ureters are sutured into a 3- to 4-cm trough in the bowel mucosa in each limb of the reservoir to create effective antireflux flap valves.

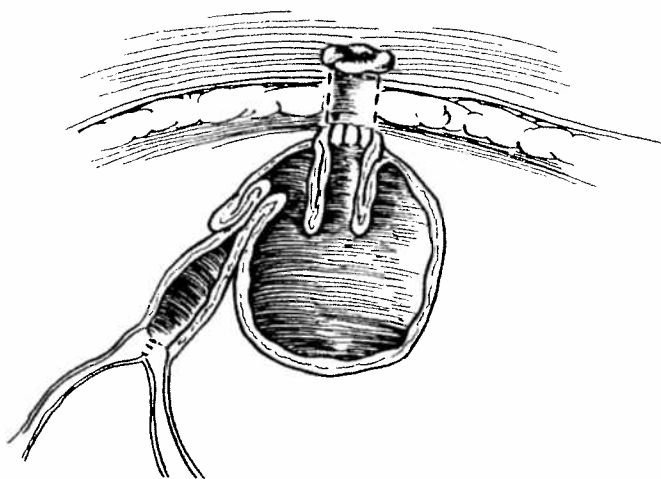


FIGURE 80-5. Kock pouch. A 70-cm segment of ileum is reformed into a peristaltic pouch with two nipple valves. Most recent modification involves fixation of nipple valve to reservoir wall, changing it to a fixed flap valve.

Additionally, gastrocystoplasty has proven to be an excellent alternative for patients with end-stage renal disease facing subsequent transplantation. The gastric neobladder has been successfully employed for reconstruction with the native urethra, the orthotopic ureteral neourethra, and with the orthotopic appendiceal neourethra. Gastric composite continent reconstructions have been reported as employing stomach and colon and as employing stomach and ileum, although long-term follow-up will be necessary to assess their effectiveness.

Ureteral Augmentation and Autoaugmentation

Ureteral augmentation (Fig. 80-7) and autoaugmentation (Fig. 80-8) hold great promise because of their ability to prevent absorptive metabolic disorders and to be performed by an entirely extraperitoneal approach. However, these procedures are more likely to fail to attain adequate capacity and compliance because of inherent restriction in surface area availability.

Internal Diversion: Procedures Providing Urinary Continence via an Intact Anorectal Continence Mechanism

Ureterosigmoidostomy

Although abandoned by most institutions because of the risks of malignancy, acidosis, and upper-tract deterioration, some centers continue to employ versions of ureterosigmoidostomy as a preferred modality for reconstruction in bladder exstrophy. Reports of series employing modern reconstructive techniques reveal quite acceptable results even with relatively long-term follow-up. In one series of 46 patients, long-term follow-up revealed one tubular adenoma, which was removed endoscopically. Upper-tract deterioration sufficient to require conversion to a colonic conduit was encountered in three additional patients. These authors use as an argument for employment of ureterosigmoidostomy in the exstrophy patient, a high incidence of unsatisfactory outcome in patients reconstructed with conventional means, including bladder-neck reconstruction and augmentation. Also noted is a significant incidence of upper-tract deterioration with primary exstrophy reconstruction on long-term

follow-up and what appears to be a significant risk of adenocarcinoma developing in the bladder exstrophy plate itself.

Sigma Rectum

The incidence of nocturnal incontinence with ureterosigmoidostomy has been addressed by procedures designed to provide a detubularized segment of sigmoid colon at the level of the ureteral reimplantation. Examples include the Mainz sigma rectum (Fig. 80-9). A similar approach has been taken with the ileorectal Kock pouch, in which a Kock pouch is anastomosed to the side of the sigmoid colon.

It is, of course, imperative that anorectal competence be documented prior to such procedures. Sufficient anorectal competence to allow continence can be assumed if the patient can comfortably maintain continence, holding an enema of volume equal to approximately 8 to 10 hours worth of urine output during normal activities without leakage.

Rectal Neobladder

Some interest has been generated with respect to various modifications of the rectal bladder. These procedures have in common a reliance upon the anorectal sphincter for continence. Additionally, the urinary reservoir is more compartmentalized. Figure 80-10 depicts the augmented and valved rectum. This procedure was performed in 83 patients with a 100% daytime continence rate and a 99% nighttime continence rate.

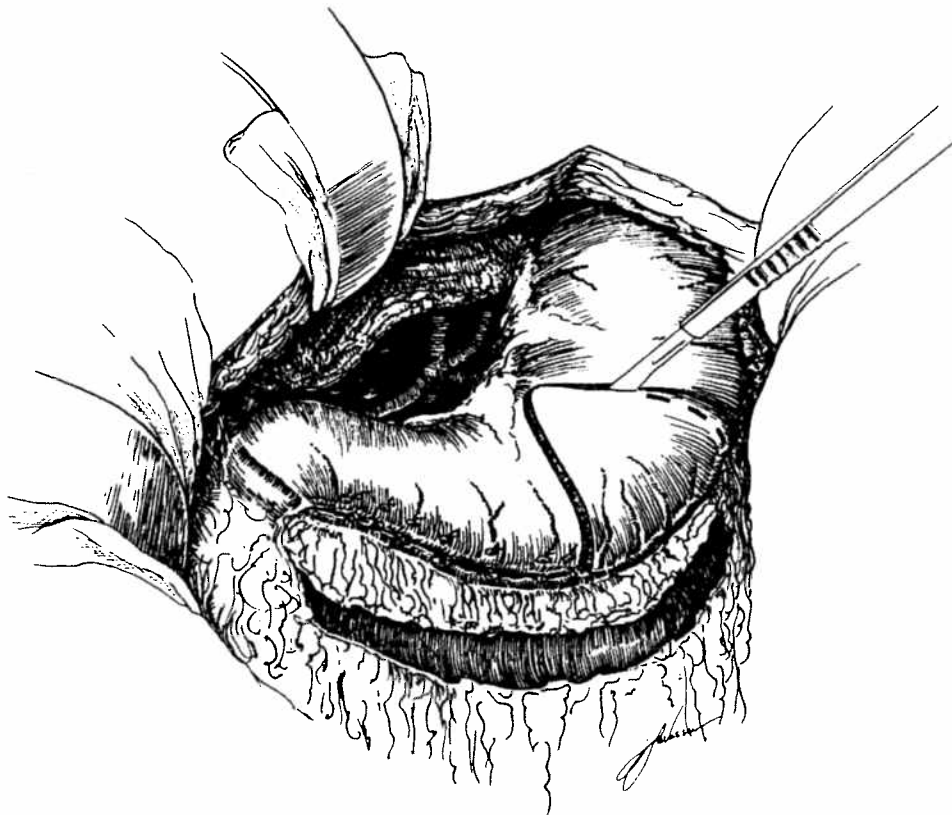Artificial Bladder

A permanently implanted, nonbiologic substitute for the bladder has been tried with such diverse materials as Vitallium, polyethylene, Teflon, polyvinyl, silicone rubber, Ivalon, Dacron, silver, Tantalum, and expanded polytetrafluoroethylene (Gor-Tex). All efforts have failed because of the development of an inflammatory reaction with or without active bacterial infection.

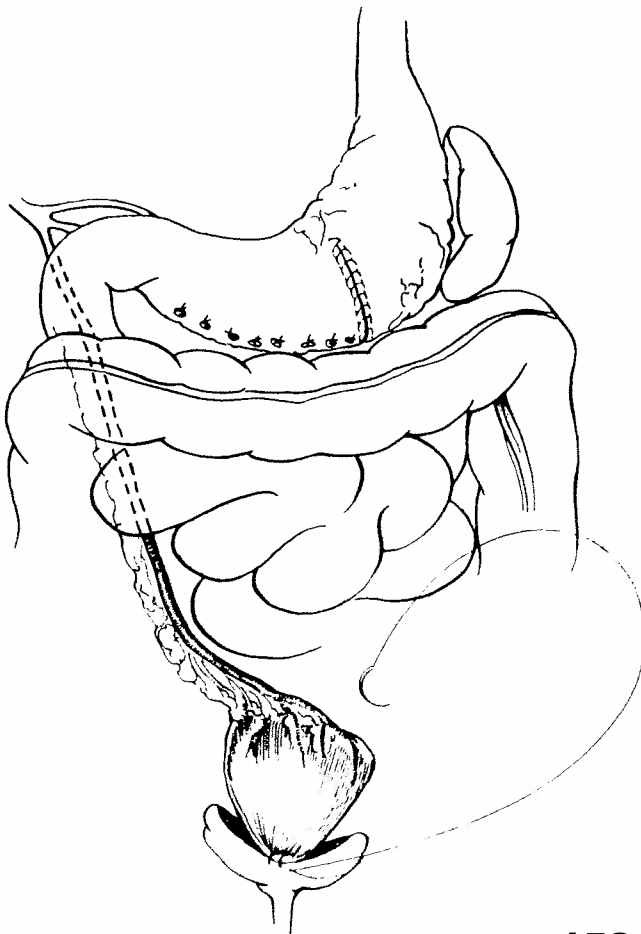COMPENSATING FOR INADEQUATE BLADDER OUTLET RESISTANCE

Urinary continence is maintained by a complex relationship between bladder outlet resistance and pressure. To maintain dryness, the bladder outlet resistance must exceed intravesical pressure not only at rest but during changes in posture, coughing, sneezing, and straining. There are several components to this mechanism. Certainly, intrinsic urethral resistance caused by inherent tension in the urethral wall as well as the length and diameter of the urethra play an important role. Other components include smooth and striated muscular activity and the fact that intra-abdominal pressure may be reflected on the proximal urethra. This latter mechanism provides a mechanism to compensate for elevated intravesical pressure caused by applied intra-abdominal pressure by simultaneously applying similar pressure to the proximal urethra.

Based on these components of continence, it is not surprising that most surgical interventions designed for the achievement of incontinence include procedures to lengthen the urethra, suspend the bladder neck, and compress the urethra. It is clear that, in males, pubertal changes can assist in creation of outlet resistance after a detrusor tube repair.



(A)



(B)

FIGURE 80-6. Gastrocystoplasty. (A) Development of right gastroepiploic pedicle and isolation of wedge of gastric fundus. (B) Mobilization of right gastroepiploic pedicle through retroperitoneal plane into augmentation position. The stomach is closed.

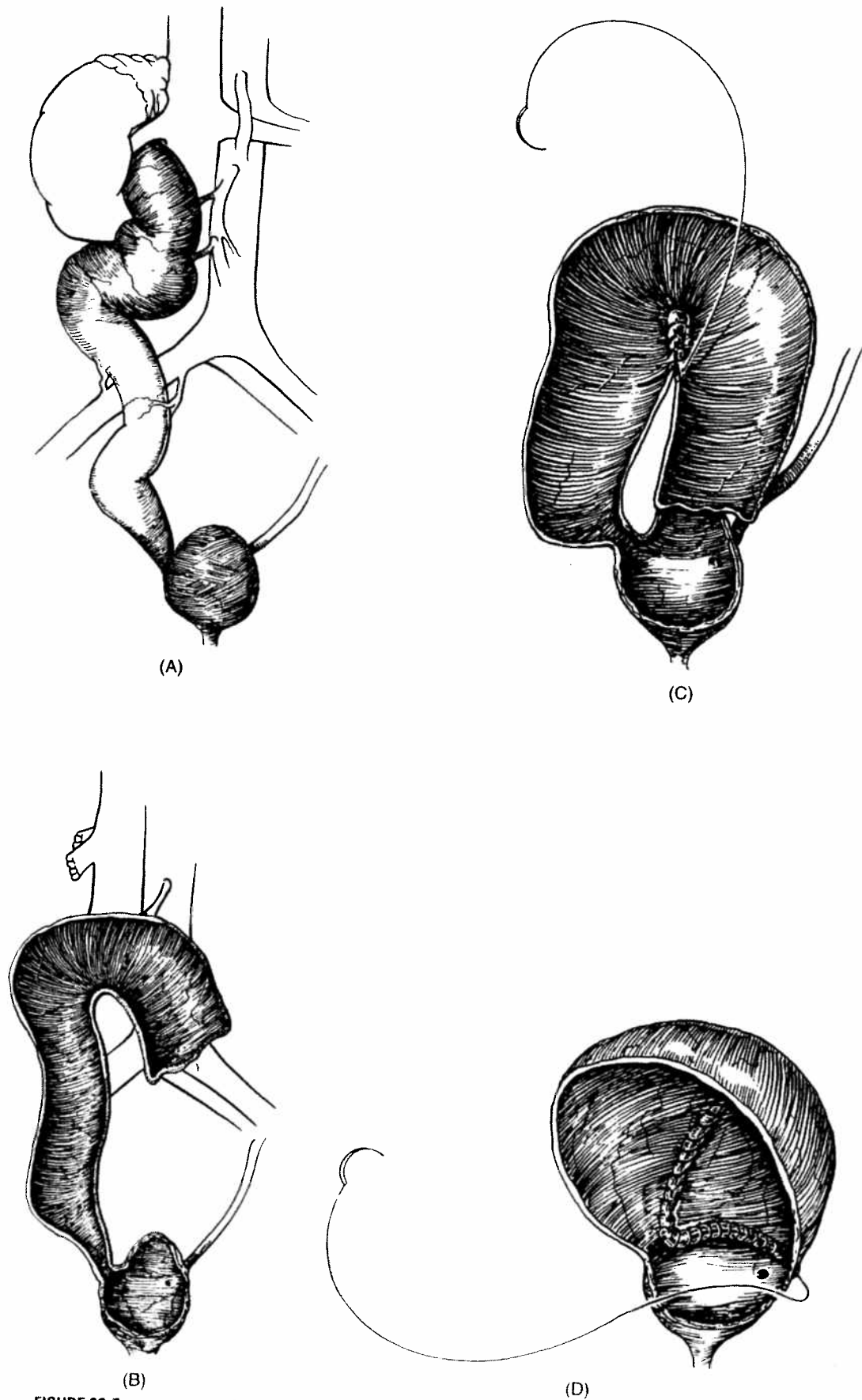


FIGURE 80-7. Operative stages of ureteral bladder augmentation. (A) Normal blood supply to ureter. (B) Ureteral detubularization following mobilization. (C) Reconfiguration of ureter into U-shaped patch. (D) Anastomosing ureteral patching to native bivalved bladder.

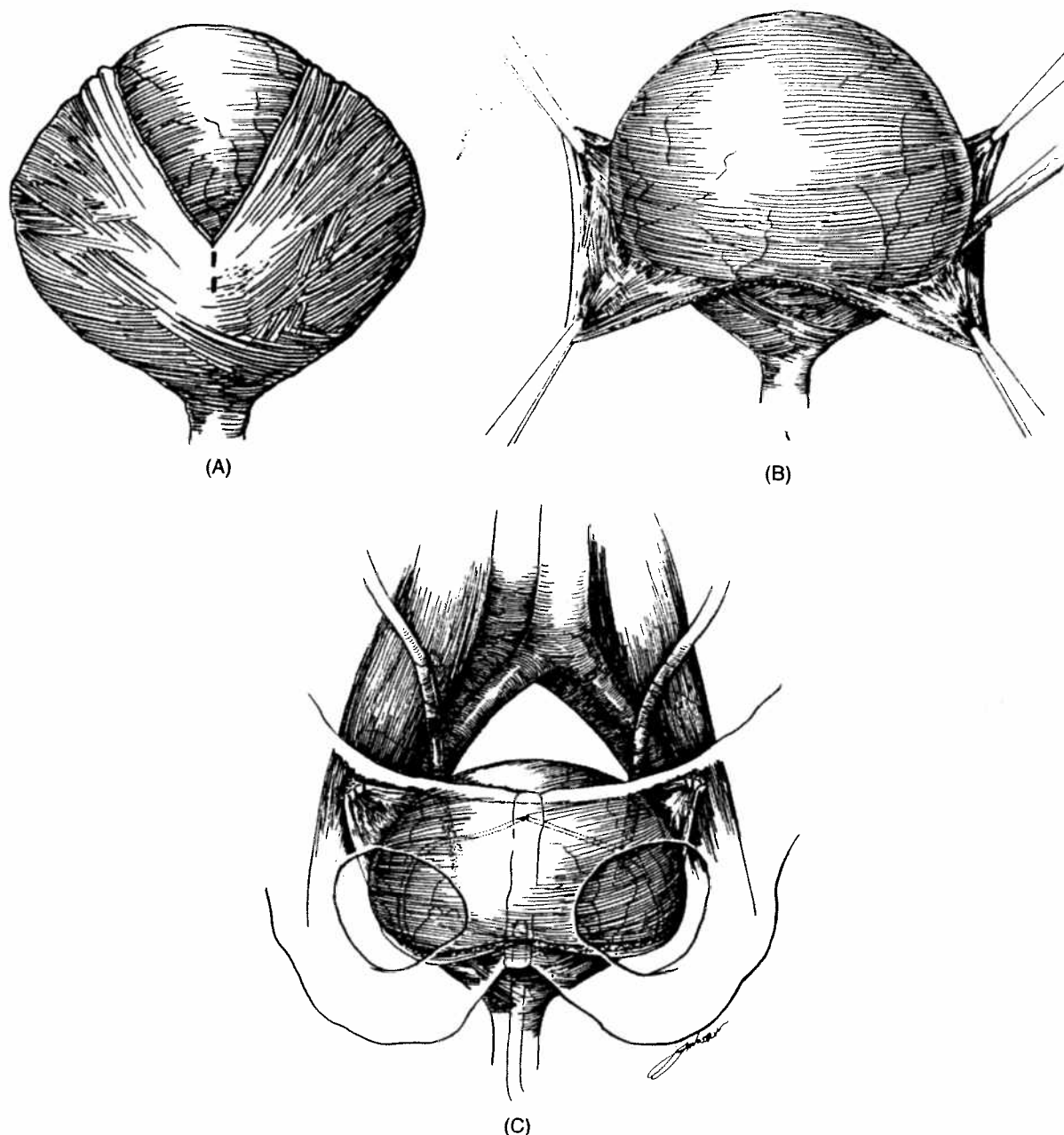


FIGURE 80-8. Diagram of autoaugmentation. (A) Detrusor incised. (B) Detrusor stripped from intact bladder epithelium. (C) Epithelium bulges with bladder filling.

Urethral Lengthening Procedures

Young-Dees-Leadbetter Procedure

Efforts to proximally lengthen the existing urethra through tubularization of the posterior detrusor grew out of the early work of Young. In his procedure, tissue in the posterior bladder neck was excised and the bladder neck was then reconstructed with narrowing. Dees' modification of this procedure involved excising more lateral mucosa and lengthening the proximal urethra toward the trigone. Leadbetter extended the construction of a long posterior detrusor tube by reimplanting ureters higher in the bladder (Fig. 80-11). He reported a 70% success rate among 27 children treated with this approach.

Other authors have had better success with the Young-Dees-Leadbetter-type reconstruction by using several modifications. Lepor and Jeffs attributed their success to a urethral suspension (Marshall-Marchetti-Krantz type of procedure) and the use of urodynamic control at the time of surgery to assure adequate urethral resistance (Fig. 80-12).

Koff reported a modification of the Young-Dees-Leadbetter procedure which he termed the *cinch* procedure. Here a muscular flap encompasses the entire circumference of the neourethra and, in addition, is suspended to the anterior abdominal wall. Hollowell and Ransley reported a large series of patients reconstructed for exstrophy. They compared the continence rate in patients who underwent bladder-neck reconstruction alone with

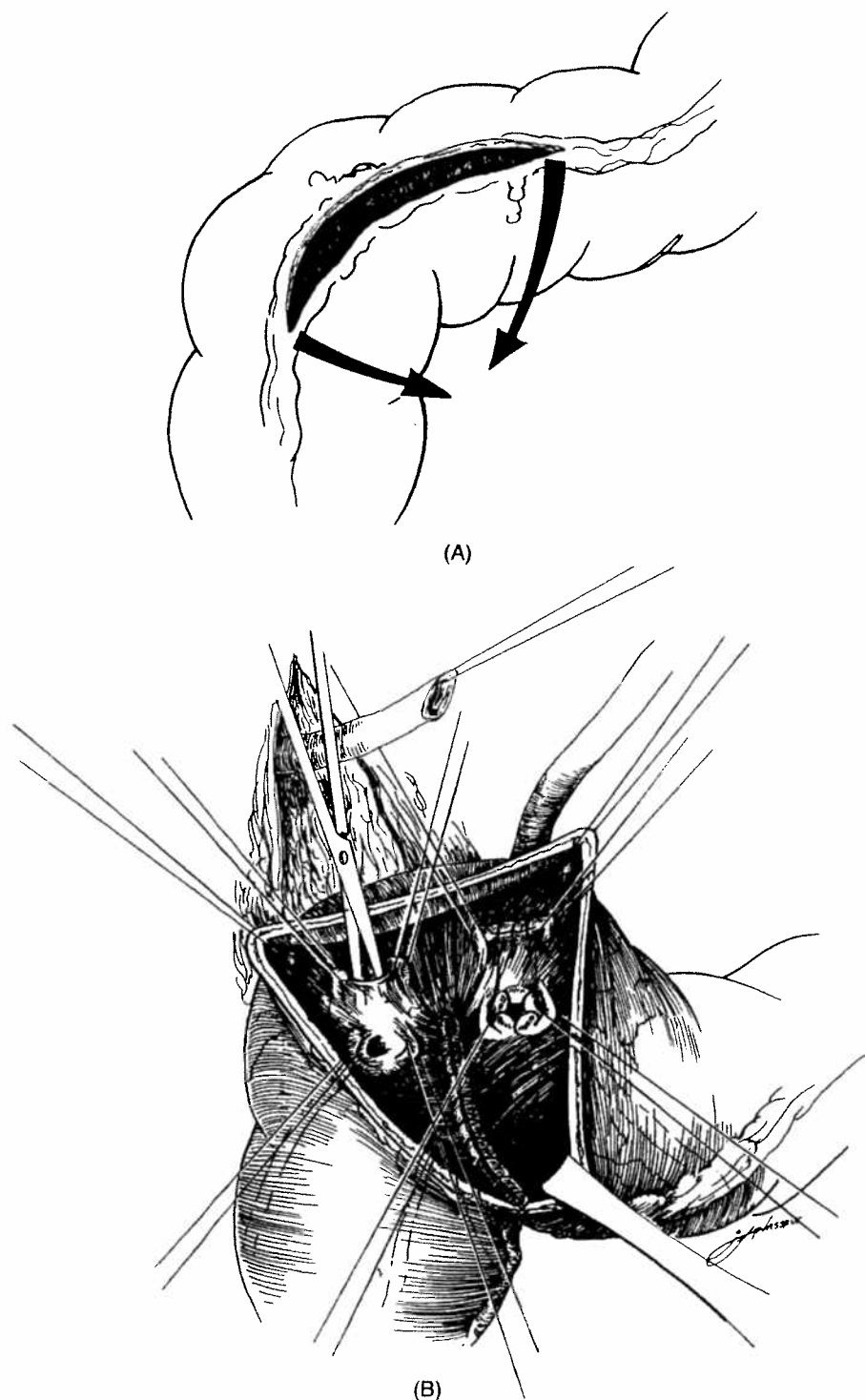


FIGURE 80-9. The Mainz pouch II (sigmoid rectum). (A) A longitudinal incision in the sigmoid colon is followed by a side-to-side anastomosis to create a detubularized segment. (B) Sacral fixation is achieved and long ureteral reimplantation is performed in the Goodwin fashion.

those who had also undergone bladder augmentation. The incidence of satisfactory continence was significantly higher in the second group.

The placement of an adjuvant Mitrofanoff neourethra in patients undergoing Young-Dees-Leadbetter bladder-neck reconstruction allows a channel for intermittent catheterization, which has been useful for all such reconstructions, especially in the early post-operative period. With time, as the patient learns to void through the reconstructed urethra, the Mitrofanoff neourethra can be removed in

a simple outpatient surgical procedure or, because it does not leak, it can be left in situ.

Kropp Procedure

Kropp described another approach to produce a competent urethra: turning the junction of the urethra with the bladder into an effective flap-valve as is seen at the normal ureterovesical junction (Fig. 80-13). A detrusor tube is formed anteriorly or posteriorly

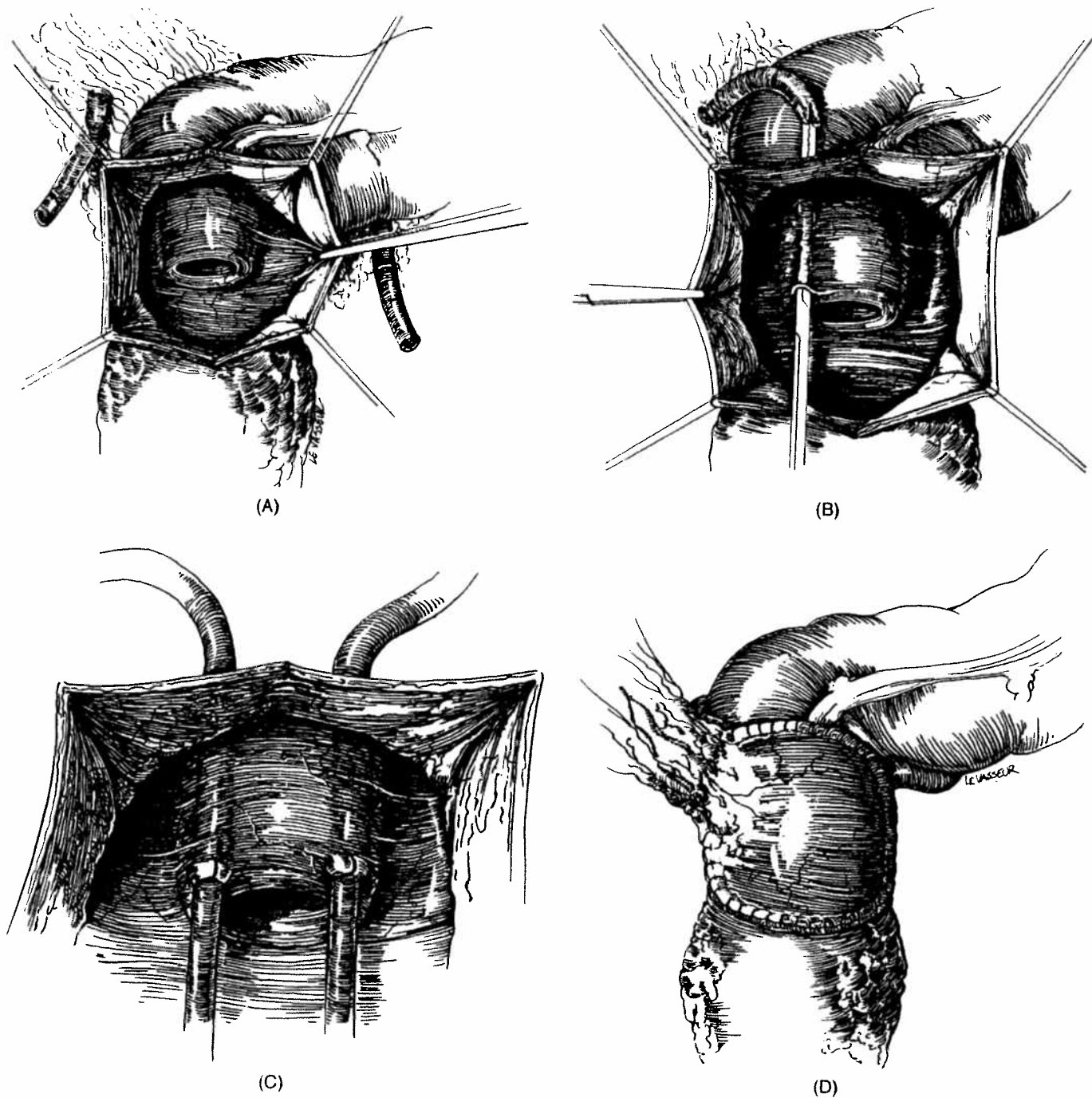


FIGURE 80-10. The augmented and valved rectum. (A) The anterior wall of the rectosigmoid is opened and a col-orectal intussusception valve is created. (B) The ureter is passed between the two layers of the intussusceptum. (C) A stented mucosa-to-mucosa anastomosis is completed on both sides. An alternative (currently the method of choice) is to reimplant the ureters through a submucosal tunnel by using Goodwin's technique. (D) The opened rectum is closed with an ileal patch.

in continuity with the bladder neck and urethra, and reimplanted submucosally in the bladder. Compression of the detrusor tube as the bladder fills creates an effective flap-valve mechanism, producing continence. Although excellent continence is achieved with such a flap-valve mechanism, spontaneous voiding is not possible in this situation, and intermittent catheterization is required for bladder emptying. The main postoperative problem is difficulty with catheterization.

Pippi Salle Procedure

Problems with catheterization after the Kropp procedure were addressed by Pippi Salle. In his technique, the mucosa of an anterior bladder wall-flap based on the urethra is sutured to posterior wall mucosa in an onlay fashion. A second layer of sutures approximates the muscle of the flap to the posterior detrusor. The remaining mucosal edges are approximated over the lengthened urethra. The reports of this procedure are encouraging.

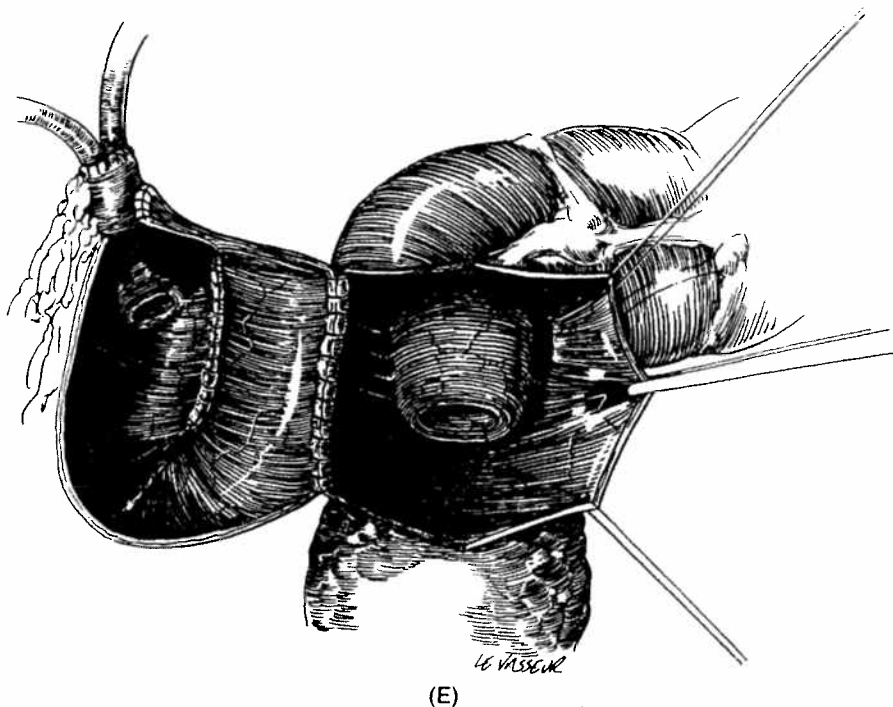


FIGURE 80-10 continued. (E) With dilated ureters, a second intussusception valve from ileum is used for reflux prevention.

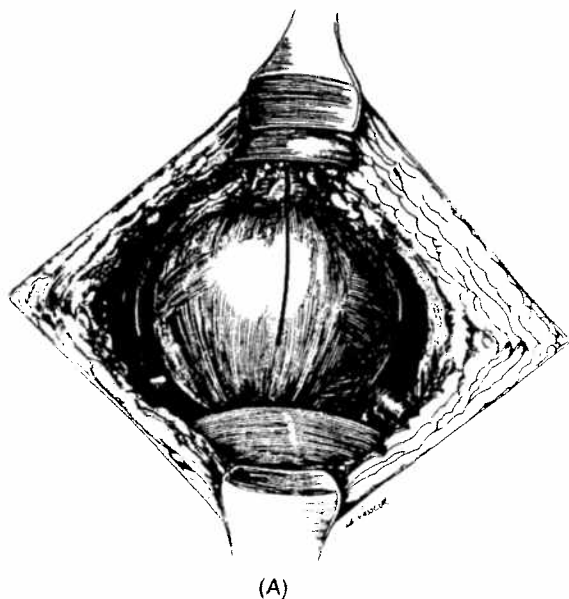
Bladder-Neck Suspension and Fixation

Open Bladder-Neck Suspension

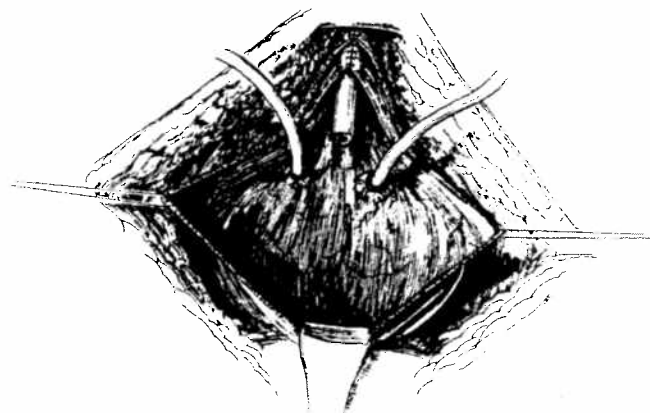
These procedures were designed primarily for the correction of stress urinary incontinence related to an abnormally low positioning of the urethrovesical junction. Increased intra-abdominal pressure could not be transmitted to the urethra, with a resultant low-pressure gradient between the bladder and the urethra, leading to stress urinary leakage during periods of increased intra-abdominal pressure. Restoration of normal anatomy should lead to correction of stress incontinence without the production of problems with bladder emptying, provided that detrusor function is normal. The urethral suspension proce-

dures may also produce urethral stretch and thus lengthening, urethral narrowing, and/or urethral compression, which may also increase bladder outlet resistance.

The urethral suspension and fixation procedure that has become the standard against which others have been compared is the Marshall-Marchetti-Krantz operation. In this open operation, the urethra is suspended from the posterior aspect of the pubic bone or rectus fascia with a series of absorbable sutures, which most surgeons today place into the periurethral tissues adjacent to the urethra. In elevating this tissue, the endopelvic fascia is also tightened. This suspension brings the urethrovesical junction to a position where increases in intra-abdominal pressure are directly transmitted to the urethra, thus correcting stress incontinence.



(A)



(B)

FIGURE 80-11. (A) Bladder incision. Leadbetter technique of tubularization of posterior detrusor. (B) Ureters are reimplanted higher in bladder to permit creation of a long detrusor tube.

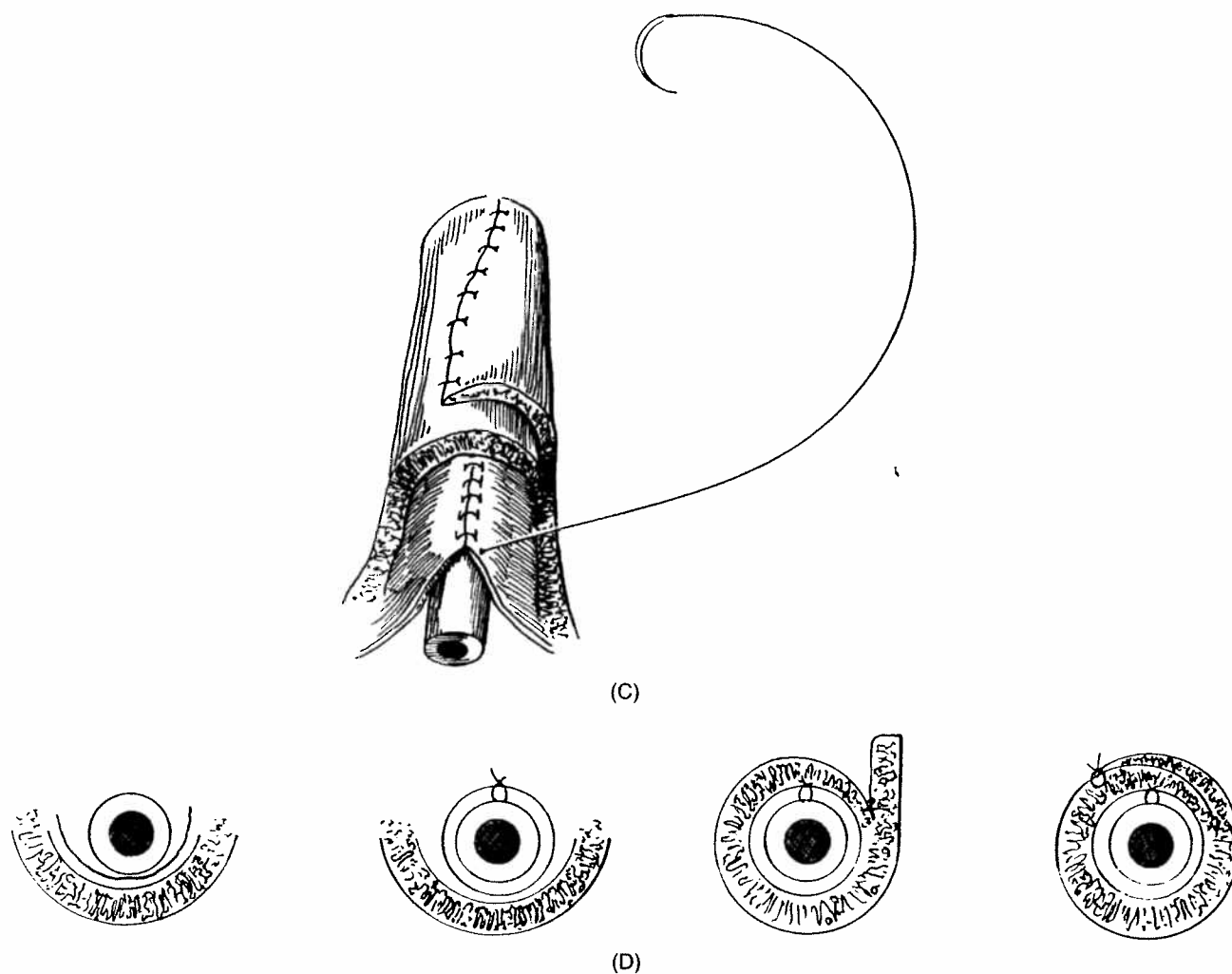


FIGURE 80-11 *continued*. (C and D) The detrusor is overlapped over the mucosal tube.

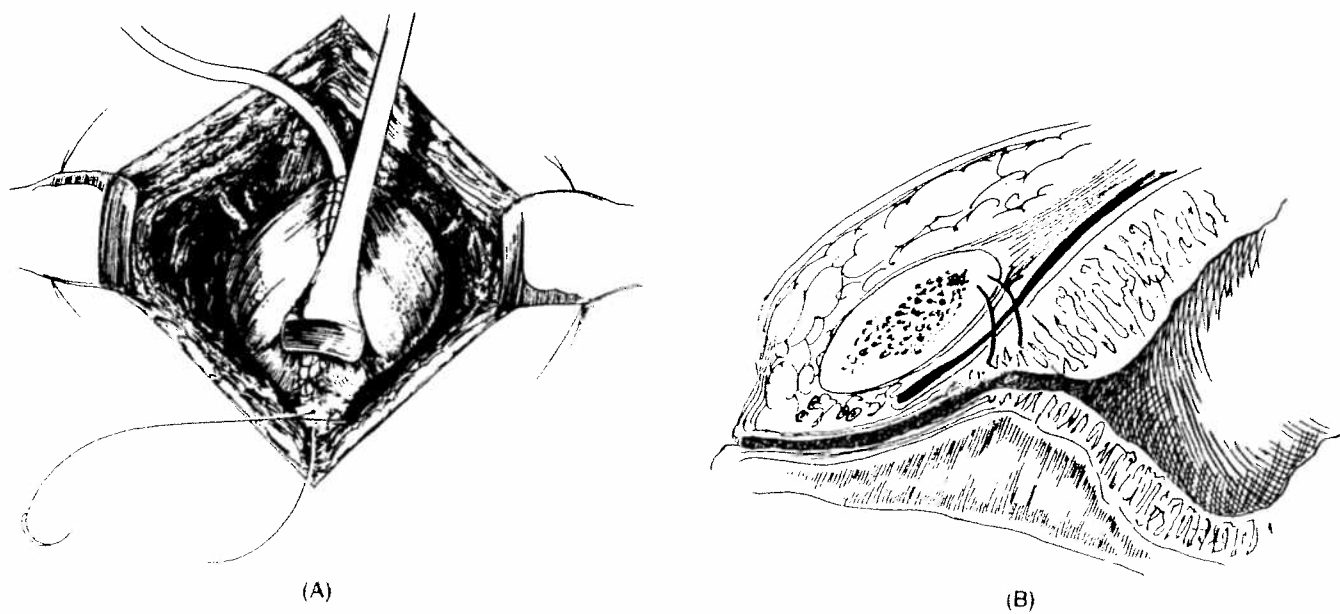


FIGURE 80-12. (A) Posterior detrusor tube suspended from posterior surface of pubic bone and rectus muscle. (B) Suspension helps preserve both length and position of detrusor tube.

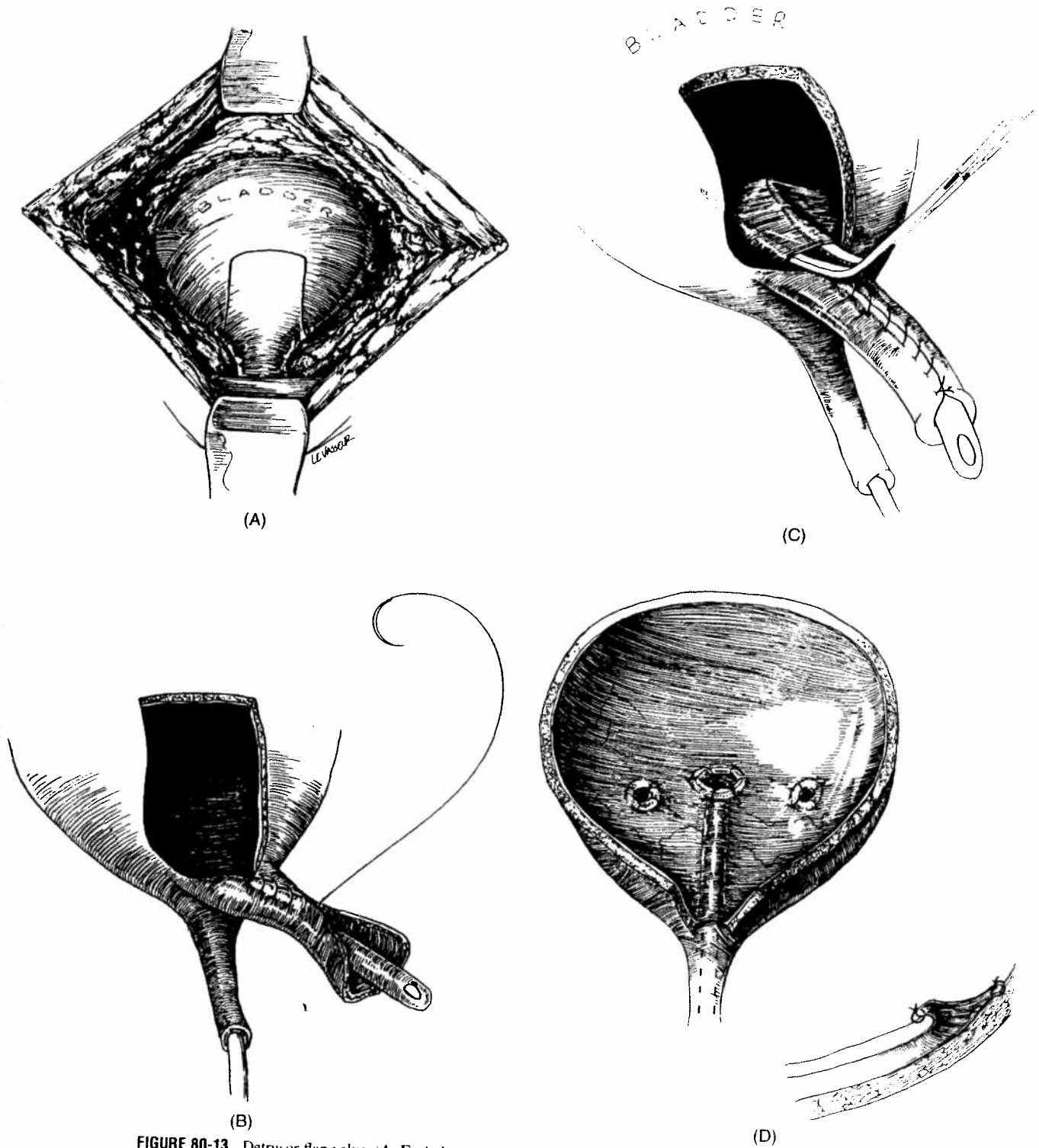


FIGURE 80-13. Detrusor flap valve. (A–E) A detrusor tube is created (anterior shown, posterior tube also possible) and tunneled submucosally in bladder to create a competent flap valve.

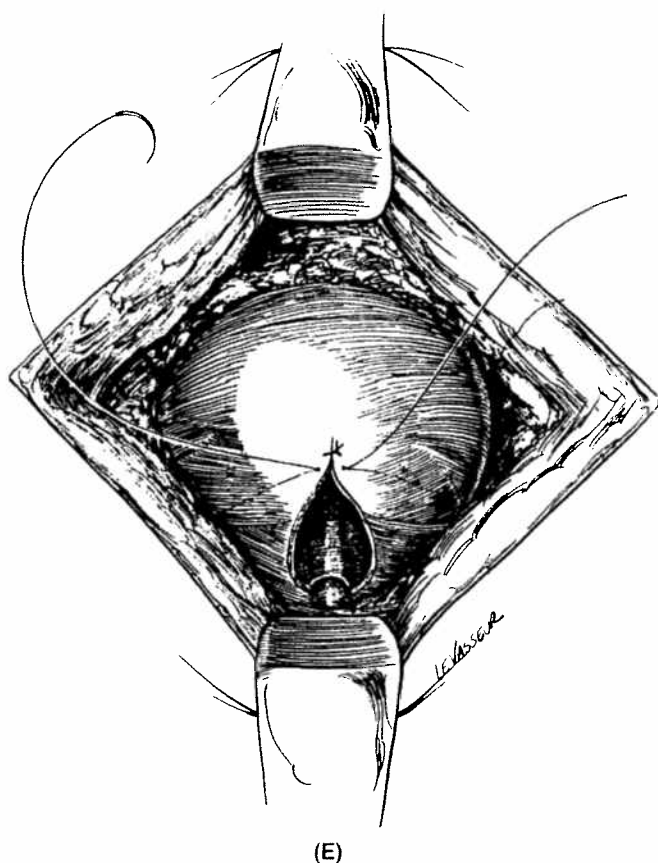


FIGURE 80-13 continued.

The Burch procedure is a similar operation to elevate the urethrovesical angle; however, in this operation, vaginal fascia near the urethra is sutured to Cooper's ligament (ileopectineal ligament). The possible advantage of this operation is that the ileopectineal ligament may provide a more reliable anchor for sutures than the periosteum of the pubic bone. Additionally, osteitis pubis is avoided.

Endoscopic Bladder-Neck Suspension

As it became clear that urethral suspension operations had much to offer in the treatment of stress urinary incontinence, the development of semiclosed needle suspensions offered a logical progression, and the original Pereyra procedure has been modified in a number of ways.

Endoscopic suspension was first described by Stamey. His innovation was to emphasize the use of the cystoscope to control accurate placement of the suspending sutures exactly at the urethrovesical junction so as to ensure appropriate urethral suspension. In the Raz needle suspension procedure, Stamey's technique is further modified. During vaginal dissection the retropubic space is entered and mobilization of the urethra and bladder neck is performed to be certain that the urethra can be moved sufficiently intra-abdominally to expose it to intra-abdominal pressure. To ensure adequate fixation of the suspension sutures to the periurethral tissues, a serial helical stitch is placed to encompass the endopelvic fascia, as well as the full thickness of the vaginal wall, except for the epithelium. This enables a broadly secured anchoring of the suture to the periurethral tissues. Suprapubically, the suspending sutures are elevated to be certain that closure of the bladder neck is occurring (as confirmed by cystoscopic inspection) and these are then tied to one another.

Fascial Sling Procedures

There is a significant difference between the suspension-type procedures and those procedures that involve some form of sling suspension of the urethra. This type of approach dates to the Millan suspension. In this operation, the rectus fascia is exposed, and two longitudinal strips of rectus fascia are dissected just above the insertion of the rectus into the pubic bone, maintaining their continuity with the rectus fascia laterally on each side. The Retzius' space is dissected and the bladder-neck region and urethra are separated from the vaginal wall. The rectus strips are brought into Retzius' space lateral to the rectus muscle, passed beneath the urethra at the bladder neck, brought back suprapubically through the midline incision between the rectus muscles, and then sutured to the anterior rectus fascia with sufficient elevation of the bladder neck to ensure intra-abdominal positioning of the urethra. The biggest drawback of this procedure has been a significant problem with long-term urinary retention. Direct compression of the urethra by the fascial strip would add to bladder outlet resistance and explain the different outcome from simple suspension. Sling procedures, particularly with the use of foreign material, can occasionally result in erosion of the urethra or bladder neck.

Sling urethral suspension procedures have been modified by combining them with needle suspension. In the Raz technique of transvaginal needle suspension of the bladder neck with a fascial sling, a rectus fascial patch is fashioned like a hammock to cover the length and width of the urethra. Four polypropylene (Prolene) sutures are placed at each corner of the graft and are drawn suprapubically with a Stamey-type needle as in an endoscopic suspension. Upward elevation of the suspending sutures lifts the entire urethra and/or bladder neck unit and compresses it through the action of the patch. McGuire modified this technique by using only two sutures with bolsters to pull upward a smaller rectus fascial strip with the same technique as a Stamey suspension.

Elder reported 14 children with myelomeningocele who were treated employing a free rectus fascia graft sling. Of these, 13 patients were augmented. Twelve patients (86%) were completely dry on intermittent catheterization, while one is dry during the day and wet at night. The remaining patient is completely incontinent. This series clearly demonstrates the utility of this technique in patients with neurogenic bladders.

Direct Urethral Compression by Foreign Body

There has been considerable interest and progress in the production of increased bladder outlet resistance through the use of external compression of the urethral lumen during the last 20 years, as non-reactive polymers of varying types have been developed.

Periurethral Injection

Direct passive urethral compression through the periurethral injection of Teflon (polytetrafluoroethylene) paste was suggested initially by Politano. The raising of a submucosal wheal of Teflon paste coapts the urethral wall, increasing bladder outlet resistance and preventing the transmission of intra-abdominal pressure to the urethra through a column of urine in an open bladder neck and/or posterior urethra.

In the female, a 17-gauge needle attached to a mechanical syringe is inserted at the urethral meatus and advanced periurethrally toward the bladder neck. Several cubic centimeters of Teflon paste are injected and the injection is continued as the needle is withdrawn. The procedure is performed usually at the 3, 6, and 9 o'clock positions around the urethra. During injections, a cysto-

scopic inspection of the bladder and urethra ensures that perforation of the needle into the lumen has not occurred. In the male, a cystoscope is left in the urethra to inspect the area of the bladder neck and prostatic urethra while the injection is performed by means of a needle tip placed in the area of the external sphincter. In a report of 165 patients treated for incontinence caused by various factors, Politano reported an overall good-to-excellent result in 75% of cases.

Possible worrisome complications have been reported. On short-term follow-up there was evidence of migration of the Teflon particles to the pelvic lymph nodes and lungs. In seven animals studied for a longer period, Teflon particles were found in the pelvic nodes, lungs, and brain of all, in the kidneys of four, and in the spleens of two. These findings have raised significant questions regarding the use of Teflon injections, particularly in children. The Food and Drug Administration has not yet cleared the use of Teflon paste in the urinary tract. The initial experience with the similar use of a collagen implant has been reported.

Artificial Urinary Sphincter

The most popular artificial urinary sphincter is the American Medical Systems' model 800 (Fig. 80-14), which consists of a cuff placed around the bladder neck or bulbar urethra, a reservoir placed intra-abdominally, and an activating pressure bulb located in the scrotum or labia; it was introduced in 1984. Controlled pressure is maintained in the cuff until the pump is squeezed, transferring fluid from the cuff into the reservoir balloon and permitting bladder emptying to take place. A delay-fill resistor in the control mechanism provides 1 to 2 minutes of lowered intraurethral pressure before automatic refilling of the cuff takes place from the reservoir balloon.

Multiple mechanical problems have occurred in patients with the artificial sphincter in place. The most common problems have been fluid leaks from the cuff or tubing kinks requiring surgical revision. The most serious complications are erosion of the sphincter into the urethra or the development of infection around the cuff.

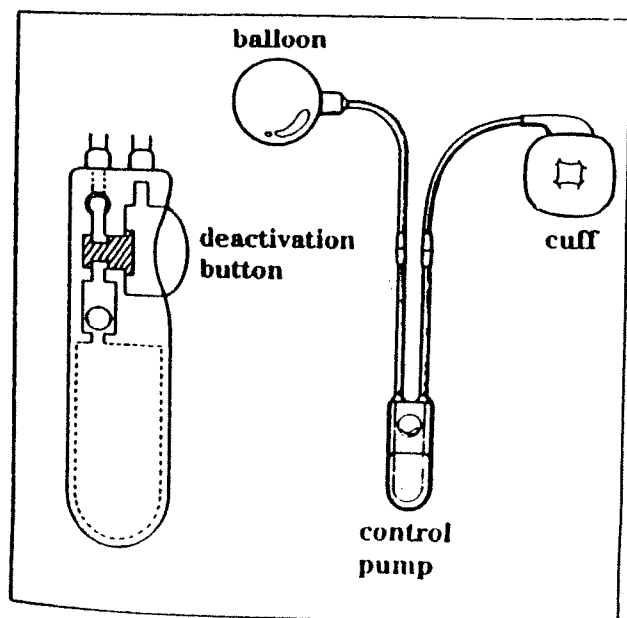


FIGURE 80-14. American Medical Systems' model 800 artificial urinary sphincter. It is a simplified model with deflation pump, delay-fill resistor, and deactivation button in one control unit that can be implanted in the scrotum or labia. (From American Medical Systems, Minnetonka, MN. Publication 30831. Used with permission.)

The latter problems generally require removal of the device. The latest modification in manufacture, which involves dip-coating the cuff with silicone and emphasis on placement of a low-pressure cuff with primary deactivation, may improve results. Mitchell and Rink recommended the routine use of a 60- to 70-cm water pressure balloon initially in children. It has been a common experience that the higher the pressure in the balloon, the greater the erosion rate. Primary deactivation to permit healing of the surgical area before subjecting the urethra to pressure appears to lower the incidence of sphincter erosion. Here, after waiting about 6 weeks, the sphincter is then activated.

It is critical that patients recognize that compliance with a program of regular bladder emptying is essential to avoid the transmission of high intravesical pressures to the upper tracts. Paradoxically, compliance has been worst in children who were rendered incompletely dry with a sphincter. Patients may become discouraged and simply stop opening the sphincter, resulting in a high-pressure bladder with secondary upper-tract damage. Long-term surveillance is critical in patients with a genitourinary sphincter in place, as late changes in the dynamics of the bladder have been reported and silent damage to the upper tracts can follow.

Alibadi further demonstrated the utility of the artificial urinary sphincter in patients in whom the sphincter was placed following earlier failed reconstruction for incontinence. Several series have documented the utility of the artificial urinary sphincter in patients who have bladder augmentation. A concern for some time has been the effect of placing an artificial urinary sphincter around the bladder neck in the male from the perspective of prostatic and sexual development. Jumper did not find any evidence for alteration in sexual development, prostatic growth, or morphology in his study employing transrectal ultrasonography.

PROVIDING FOR ALTERNATE CONTINENT URINE DRAINAGE

Physiologic Considerations

Procedures directed at urethral functional replacement are based on the creation of a tubular conduit of sufficient length that is exposed to external compressive forces, thereby providing outlet resistance that cannot be overcome by intravesical (intrareservoir) pressure. The success of these procedures in terms of continence relies upon attaining controlled reservoir-neourethral balance. Neourethral resistance to reservoir outflow must be sufficient to exceed both resting and intermittently elevated intravesical pressure associated with gravity (upright posture), as well as episodic additive intra-abdominal pressure spikes (coughing, sneezing, straining, and sudden postural changes). The creation of neourethral resistance must be complemented by low intravesical (intrareservoir) pressure. This may entail bladder augmentation or replacement by bowel, and should include reconfiguration by detubularization. A large capacity is imperative, as is intermittent catheter drainage before the low compliance portion of the reservoir's pressure-volume curve is entered. Because the reconstruction of outlet resistance to permit spontaneous balanced voiding is most difficult, the construction of a neourethra should not be undertaken if spontaneous voiding is anticipated. The patient should, however, be prepared for a possible permanent need for intermittent catheterization.

A transabdominal tube of bladder, bowel, appendix, or ureter with a sufficient length exposed to intra-abdominal pressure may provide continence through hydraulic principles. However, greater

success is achieved by supplementation with a valve mechanism, whereby a portion of the neourethral length is exposed to intravesical hydrostatic pressure. Nipple and flap valve mechanisms are used most commonly.

A nipple valve is a lumen within a reservoir created by the inversion of a tubular conduit. This most commonly takes the form of ileocecal or ileal-ileal intussusception. The circumferential application of intrareservoir pressure causes luminal collapse and sufficient resistance to prevent egress of urine. This valve is subject to an inherent instability resulting from the fact that the same forces that achieve luminal collapse cause anatomic distraction at the base of the nipple, resulting in valve shortening and, often, eventual incompetence (Fig. 80-15).

The flap valve is also a lumen within a reservoir, but in this instance, all or a portion of the conduit is supported against the inner surface of the wall of the urinary reservoir. Here, intrareservoir pressure collapses the internal lumen and, if the compressed channel is well-anchored to the reservoir wall, additional intrareservoir forces simply add to compression of the channel and are not disruptive to the flap-valve mechanism. This is the mechanism that underlies the normal competence of the ureterovesical junction.

Probably the most important adjunct to the efficiency and longevity of these valvular mechanisms is their exposure to low reservoir pressures. Thus, the creation of a low-pressure reservoir, as reviewed previously, is an essential component in the construction of a competent neourethra. Once constructed, these neourethras have the potential for anastomosis to the residual native urethra (if present) or for the creation of a continent anterior abdominal or perineal stoma.

Mitrofanoff Principle

In 1980, Mitrofanoff first reported the use of appendix and ureter as catheterizable conduits attached to the bladder via a flap-valve antirefluxing technique, with the proximal end brought out to the skin

to enable clean intermittent catheterization. The Mitrofanoff principle can be summarized as consisting of two components: (a) a narrow supple conduit (most frequently the appendix or ureter) is brought to the skin as a catheterizable stoma; and (b) antirefluxing insertion of this conduit into the reservoir provides continence by a flap-valve mechanism (Fig. 80-16).

Mitrofanoff's concept and extension of these principles have permitted continent reconstruction of the lower urinary tract in a wide variety of situations. The small caliber of the catheterizable conduit permits the simple creation of an effective flap-valve mechanism by placing a portion of the conduit in a submucosal position within the reservoir, and facilitates catheterization by helping to avoid problems with kinking and coiling catheters.

Table 80-1 outlines the recent experience with various modifications of the Mitrofanoff principle. This experience encompasses 159 patients, of whom 98 (62%) had their neourethra constructed from appendix. Ureter was used in 42 (26%) patients and tapered ileum in 10 (6%) patients. Also employed were two tubes constructed of bladder, hind gut, stomach, vas deferens, and fallopian tube. Ninety-six percent of patients were reported as achieving ultimate continence. The most common complication was that of stomal stenosis, requiring stomal revision. Mitrofanoff neourethras that could not be negotiated, or which were lost because of ischemic necrosis, were only rarely encountered. The appendix was found to be the most reliable conduit for achieving continent catheterization access.

The Mitrofanoff neourethra concept has proven extremely versatile and has been implanted into bladder, colon, and stomach with equal efficiency. The flexibility of this technique is also exemplified by the ability to externalize the Mitrofanoff neourethra at either the anterior abdominal wall (Fig. 80-17), the umbilicus (Fig. 80-18), or the perineum (Fig. 80-19). The versatility of this technique has been enhanced by extending the length of the appendix by using tubularized cecum.

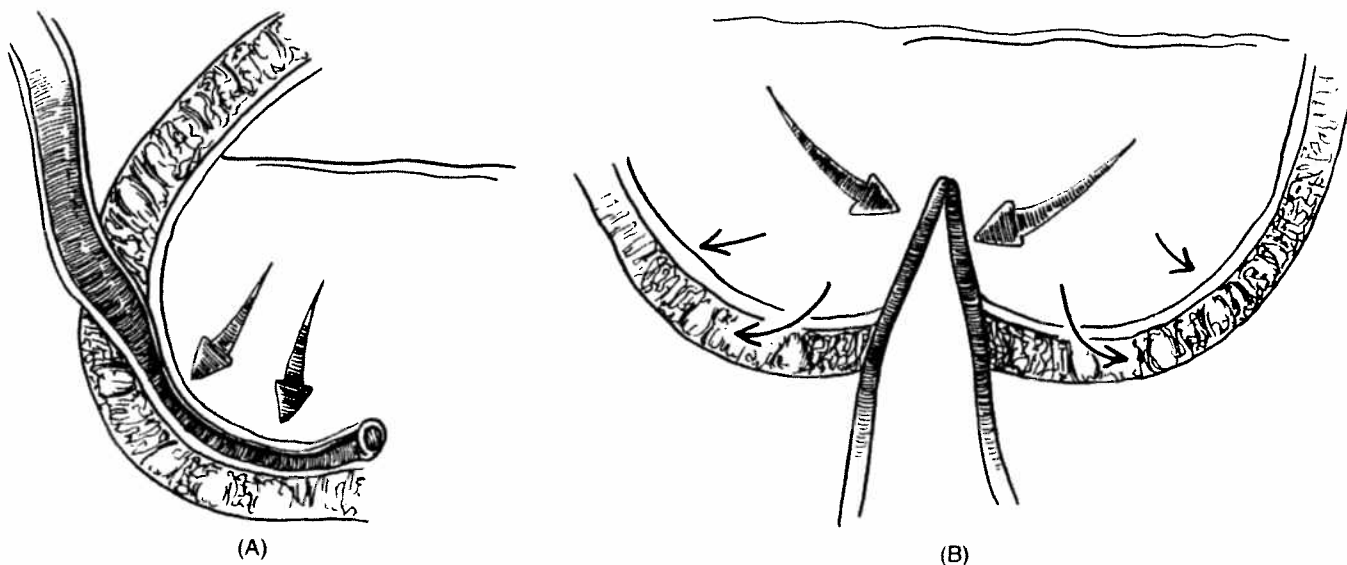


FIGURE 80-15. (A) Flap valves; (B) nipple valves. Nipple valves (B) are continent because the nipple is circumferentially compressed by pressure within the reservoir. Unfortunately, the intrareservoir pressure also has a laterally destructive force on the base of the nipple, causing a shortening or total effacement of the valve with loss of the continence mechanism. Flap valves (A) are continent because the submucosal segment is compressed by filling of the reservoir (as for a reimplanted ureter for vesicoureteral reflux). Unlike nipple valves, flap valves are stable because they are fixed to the wall of the reservoir. Thus, reservoir filling does not tend to cause loss of the continence mechanism.

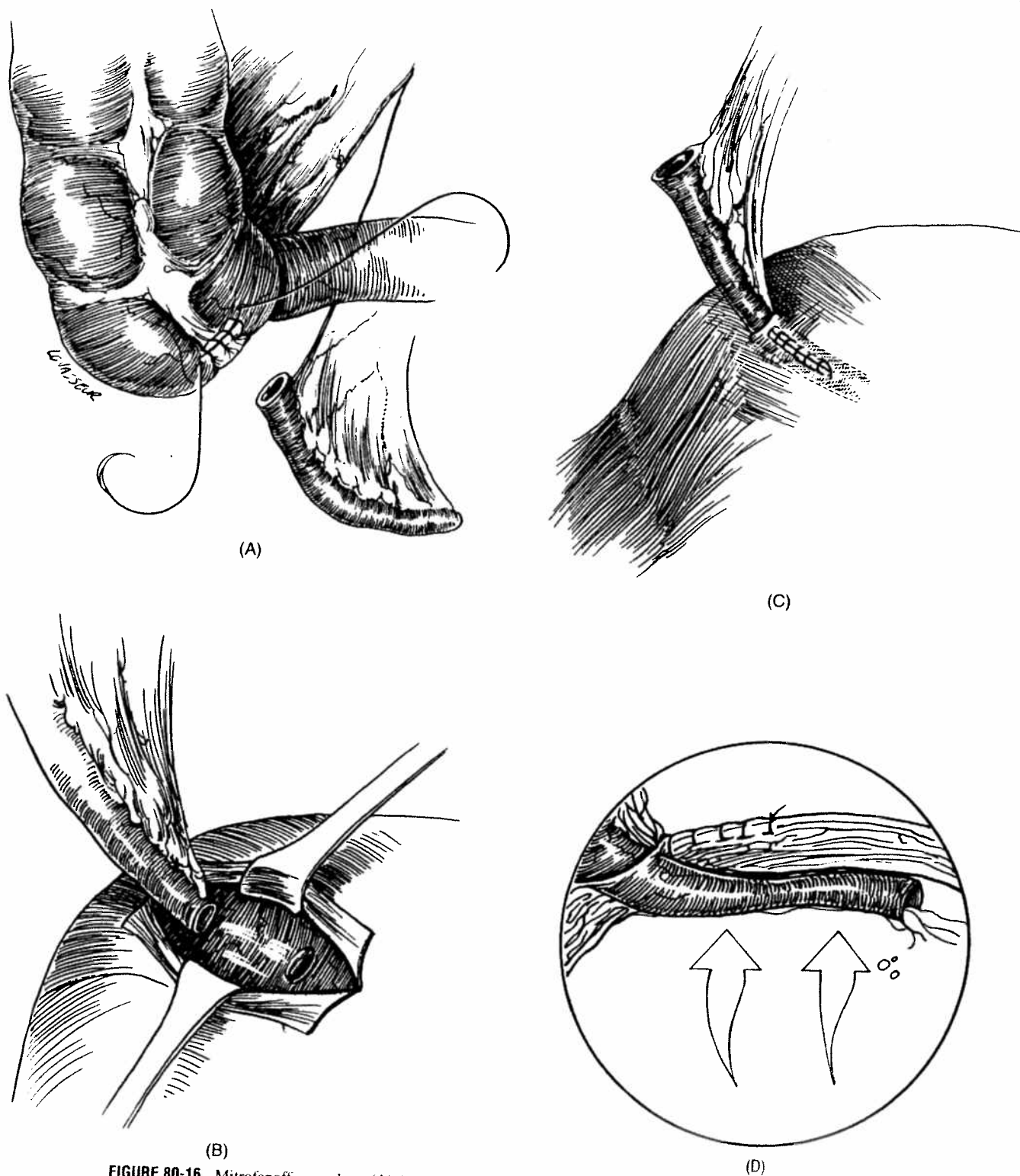


FIGURE 80-16. Mitrofanoff procedure. (A) Appendix has been mobilized on its mesentery and cecal segment is closed. (B) Extravesical dissection shows mucosal orifice in which distal end of appendix will be implanted. (C) Finally, detrusor is closed over implanted appendix and its proximal end is then brought to skin to serve as catheterizable stoma. (D) This diagram depicts resulting continent flap-valve mechanism of Mitrofanoff procedure. Similar to reimplanted ureter, a rise in intravesical pressure compresses conduit against detrusor, occluding its lumen, and achieving continence.

TABLE 80-1. Source of Mitrofanoff Neourethra and Outcome in 159 Patients from Six Recent Large Series

Series	Woodhouse, 1989	Dykes, 1991	Sheldon, 1992	Borzi, 1992	Sumfest, 1993	Duckett, 1993	Total
Number of Cases	16	28	17	10	47	41	159
Appendix	5	19	14	9	26	25	98 (62%)
Ureter	10	8	2	—	11	11	42 (26%)
Tapered ileum	—	—	1	—	4	5	10 (6%)
Bladder	—	—	—	—	4	—	4
Hindgut	—	—	—	—	2	—	2
Gastric	—	—	—	1	—	—	1
Vas deferans	—	1	—	—	—	—	1
Fallopian tube	1	—	—	—	—	—	1
Continence	14	27	17	8	44	41	152 (96%)
Stenosis	3	4	2	—	9	3	21 (13%)

From Sheldon CA, Snyder HM. Principles of urinary tract reconstruction. In: Gillenwater JY, et al., eds. Adult and Pediatric Urology. 3rd ed. St Louis, MO: Mosby Year Book, 1996:2368.



FIGURE 80-17. Typical Mitrofanoff neourethra with catheter in position. (From Sheldon CA, Gilbert A. Use of the appendix for urethral reconstruction in children with congenital anomalies of the bladder. *Surgery* 1992;112:805-812. Used with permission.)

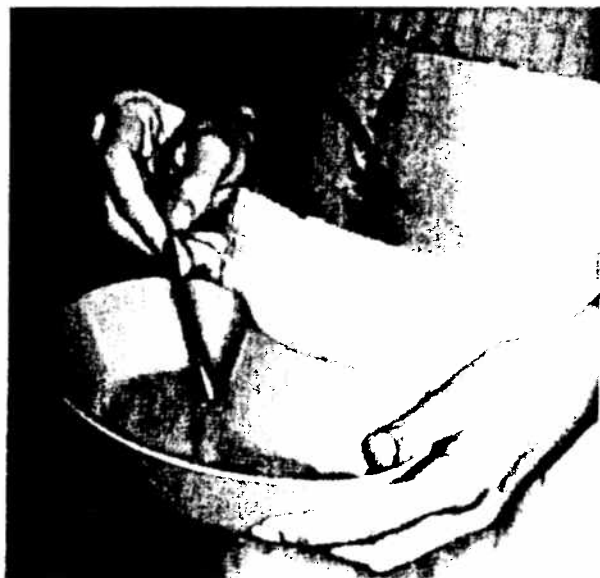

FIGURE 80-18. Inconspicuous umbilical stoma is easily catheterized by patient. (From Sheldon CA, Gilbert A. Use of the appendix for urethral reconstruction in children with congenital anomalies of the bladder. *Surgery* 1992;112:805-812. Used with permission.)

An important potential complication, subsequent to noncompliance with catheterization, is rupture of the urinary reservoir. Patients and families should be strongly cautioned regarding such an eventuality, and this possibility argues for preserving the native urethra as a "pop-off" mechanism, rather than simply dividing the native bladder outlet.

Total urethral replacement in the female and partial urethral replacement in the male is possible by employing cutaneous tubularized pedicle grafts, ureter, and appendix extended with cecum that employs a flap-valve principle. Successful replacement of the entire lower urinary tract with substitution of both bladder and urethra is now possible, as outlined in Table 80-2.

COMPENSATING FOR INADEQUATE URETERAL LENGTH

In reconstructing the urinary tract, the method by which the upper urinary system is connected to the reservoir is of great importance. Owing to the high number of patients who have had continent re-

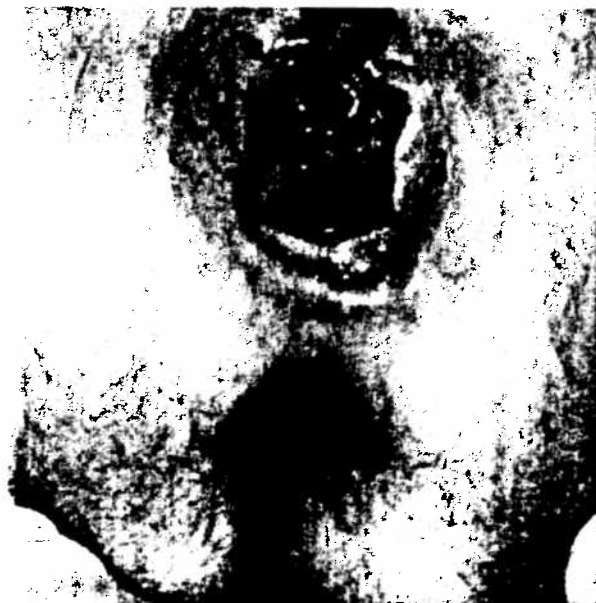

FIGURE 80-19. Neourethra brought to perineum in orthotopic position. (From Sheldon CA, Gilbert A. Use of the appendix for urethral reconstruction in children with congenital anomalies of the bladder. *Surgery* 1992;112:805-812. Used with permission.)

TABLE 80-2. Lower Urinary Substitution (Bladder and Urethra)

Series	Numbers of Patients	Neourethra	Neobladder	Continence
Mundy, 1988	8	Labia (6) Prepuce (2)	Colon Colon	5 (83%)
Mitchell et al., 1988	4	Ureter (2) Ureter (2)	Colon Stomach	7 (88%)
Sheldon and Gilbert, 1992	2	Ureter (1) Appendix (1)	Stomach Stomach	2 (100%)

From Sheldon CA, Synder HM. Principles of urinary tract reconstruction. In: Gillenwater JY, et al., eds. *Adult and Pediatric Urology*. 3rd ed. St Louis, MO: Mosby Year Book, 1996:2370. Used with permission.

construction and who require clean intermittent catheterization, the incidence of bacteriuria is high. It seems wise, particularly in children, to protect the upper urinary tract by a nonrefluxing attachment of the ureter or ureteral substitute to the reservoir. When the ureter is short or abnormal, this can pose a considerable challenge; this section reviews a number of techniques that have been used to deal with this problem.

Nephropexy

Every effort must be made to attach the upper urinary tract to the lower urinary tract without tension. Hendren showed that by wide mobilization of the kidney and ureter as a unit, an additional several centimeters can be obtained in the infant, or up to 2 to 3 inches in an older individual. Meticulous dissection is essential to the success of this technique; all retroperitoneal tissue is swept toward the ureter and kidney, to avoid damaging the segmental blood supply of the ureter. The gonadal vessels may be divided distally and also kept with the ureter, helping to preserve a segmental blood supply. The kidney is mobilized as it would be for a radical nephrectomy and maintains its attachments only through the renal hilus. With this extended mobilization, the kidney can be displaced to some extent in virtually all cases. The lower pole of the kidney is sutured to the psoas muscle with nonabsorbable sutures as low as possible without placing undue tension on the pedicle. As a major increase in length is not achieved with this extensive surgery, it is appropriate to reserve this maneuver for those cases in which some of the techniques to be mentioned below cannot be used and a small amount of further ureteral length is all that is required to ensure a good result.

Transureteroureterostomy

One of the most useful techniques in urinary tract reconstruction is that of transureteroureterostomy (TUU) (Fig. 80-20). Most reports regarding this technique have been overwhelmingly favorable. In a review of these experiences, several principles essential to the successful execution of a TUU have emerged. Wide exposure is essential and usually should be achieved transabdominally. Wide mobilization of the donor ureter (including the gonadal vessels in some cases) permits a tension-free anastomosis. If the ureter is too short to lie comfortably under the inferior mesenteric artery, then the ureter should be placed above this vessel. The anastomosis should be placed on the medial wall of the recipient ureter and, whenever possible, the latter should be left in situ without mobilization to ensure a better blood supply to the anastomosis area. Spatulation of the donor ureter should ensure a generous anastomosis with the recipient ureter. If the donor ureter is larger than the recipient ureter,

it is simply cut straight across. In a TUU, either an internal stent to divert the urine from each kidney or a nephrostomy tube is advisable to avoid extravasation of urine and subsequent fibrosis with wound contracture around the anastomosis. Meticulous attention to technique clearly contributes to the achievement of this goal.

The usefulness of TUU lies primarily in letting one good ureter provide effective drainage for two renal units. One good, long reimplant with a TUU is better than two compromised reimplants. In general, the best ureter with the least dilatation should be reimplanted into the bladder.

Psoas Hitch and Boari Flap

The bladder can often be gently stretched and surgically reshaped to permit ureteral reimplantation. The immobilization of a portion of the bladder by suturing it upward against the psoas fascia above the iliac vessels was popularized to facilitate reimplantation of a shortened ureter and permits replacement of at least the distal third of the ureter without difficulty (Fig. 80-21).

In performing a vesicopsoas hitch, it is useful to open the bladder on the side away from the proposed hitch to permit more bladder to be stretched up toward the psoas muscle. We prefer nonabsorbable sutures placed through a generous bite of the bladder wall but excluding the mucosa. With a little care, injury or entrapment of the genitofemoral nerve can be avoided.

The Boari flap is an extension of the concept of a vesicopsoas hitch. In this procedure, a bladder flap is formed from the front wall of the bladder with its hinge at the lateral dome of the bladder, permitting the flap to be rotated upward toward the kidney. By combining this flap with a vesicopsoas hitch, a nearly complete replacement of the ureter can be performed. Essential to the success of this flap is the preservation of a good blood supply to the bladder muscle that constitutes it. It is advisable to fix the length of this muscular flap posteriorly against the muscle of the gutter to maintain its position. After the attachment of the ureter it is tubularized as part of the bladder closure.

Renal Autotransplantation

Although renal autotransplantation is a relatively rare way of dealing with the short ureter it may be the only approach in certain situations.

Intestinal Ureter

In recent years, there has been an increased use of small bowel (ileum) for ureteral replacement as part of urinary tract reconstruction in children and young adults (Fig. 80-22). It is critical that the ileal ureter be isoperistaltic. For replacement of the right ureter, the

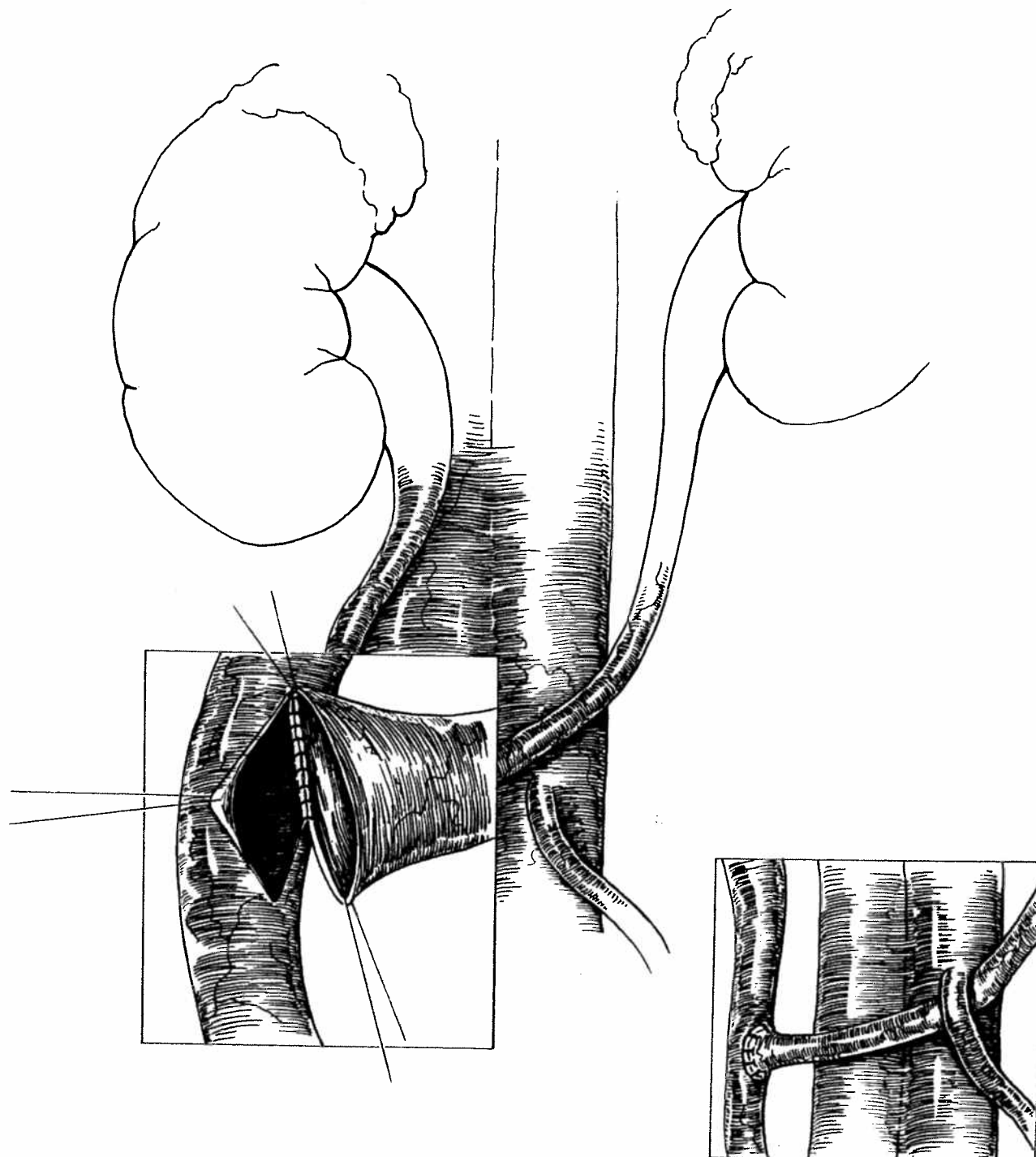


FIGURE 80-20. Transureteroureterostomy. Meticulous attention to technical detail and avoidance of tension gives a high success rate. Insert demonstrates passage of ureter inferior to the inferior mesenteric artery.

mesentery of the ileum must be rotated 90 degrees. A widely spatulated anastomosis to the renal pelvis or lower-pole infundibulum and a direct anastomosis to the back wall of the bladder near the trigone is usually performed. Distal tapering appears to be important in achieving an antirefluxing anastomosis of the ileal ureter to the bladder. A suitable bladder is, however, critical. The use of the vesicopsoas hitch not only permits a longer submucosal tunnel, but also fixes the new hiatus, helping to avoid angulation and kinking

with bladder filling. Even if all these points are meticulously followed, there is a 25% reflux rate after ileal ureter tapering and implanting into the bladder.

An additional complication that is emerging with the use of ileal ureters is the late development of stricture. Perhaps the problem could be avoided if urine sterility could be maintained consistently, but this is difficult to achieve in the reconstructed urinary tract that is emptied by clean intermittent catheterization.

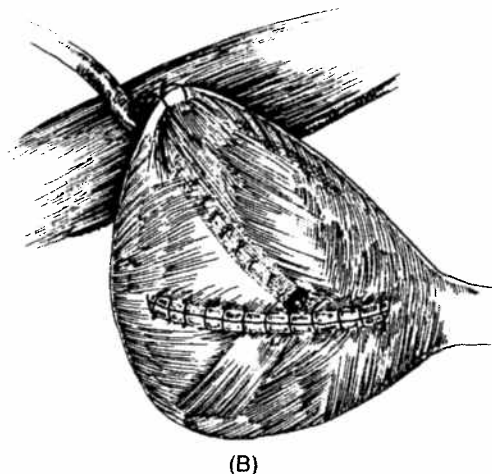
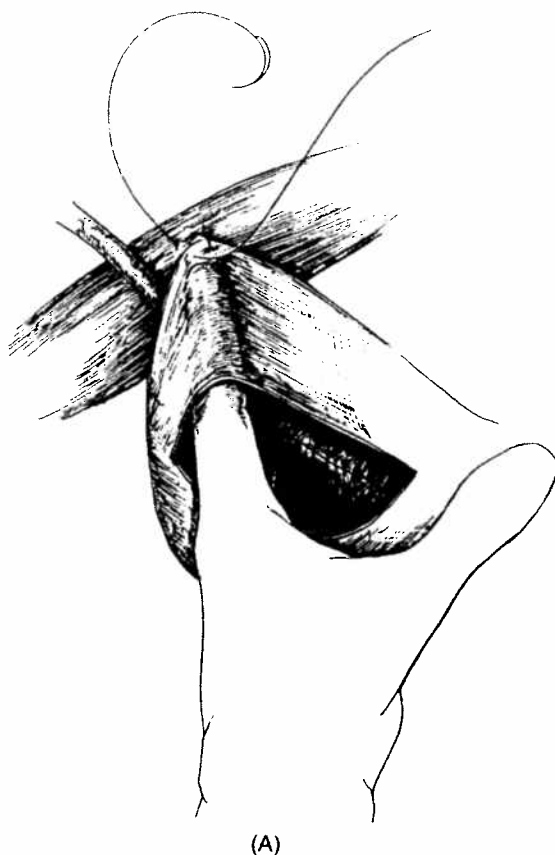


FIGURE 80-21. Vesicopsoas hitch. (A) Stretch of the bladder and fixation to psoas muscle permits a good reimplant of a short or dilated ureter. (B) The Boari flap is an extension of this technique, with a broad flap of detrusor hinged at the bladder dome.

Greater success with bowel ureters may be achieved if they do not require anastomosis to the bladder. Casale et al have had success with the interposition of a bowel segment to bridge a ureteral gap. The bowel segments were not tapered and appeared to drain well. This may be a promising technique when there is a useful distal ureteral segment that cannot be joined to the upper urinary tract by the means covered earlier.

COMPLICATIONS

Reconstructive Failure

Reconstructive failure encompasses upper-tract deterioration, failure to store, and/or failure to empty. Upper-tract deterioration may be associated with obstruction, reflux, infection, or inadequate

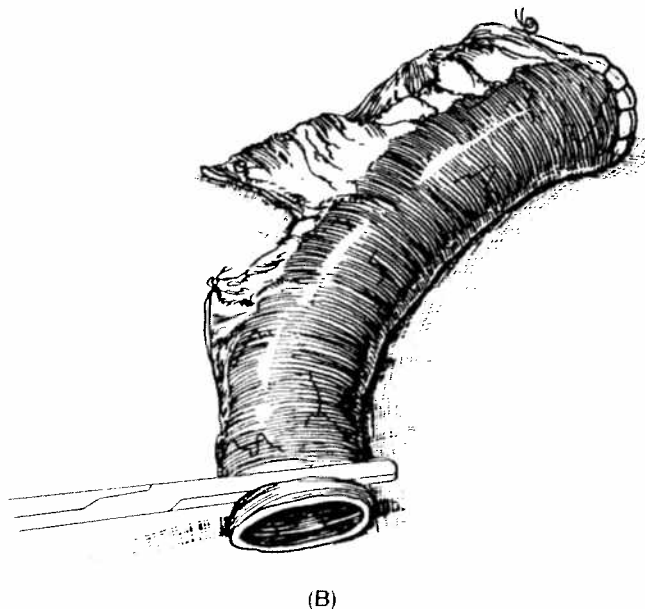
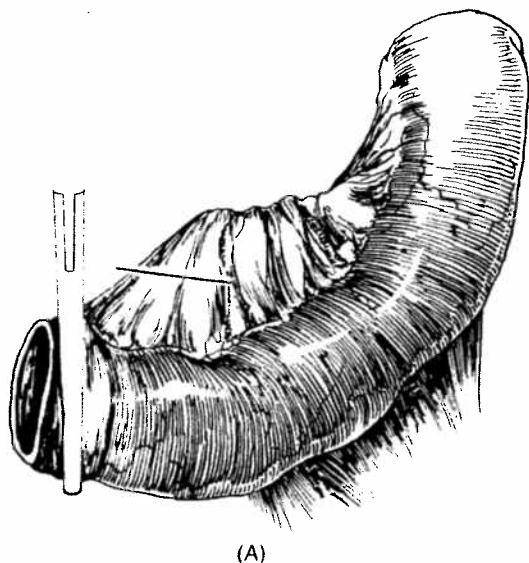
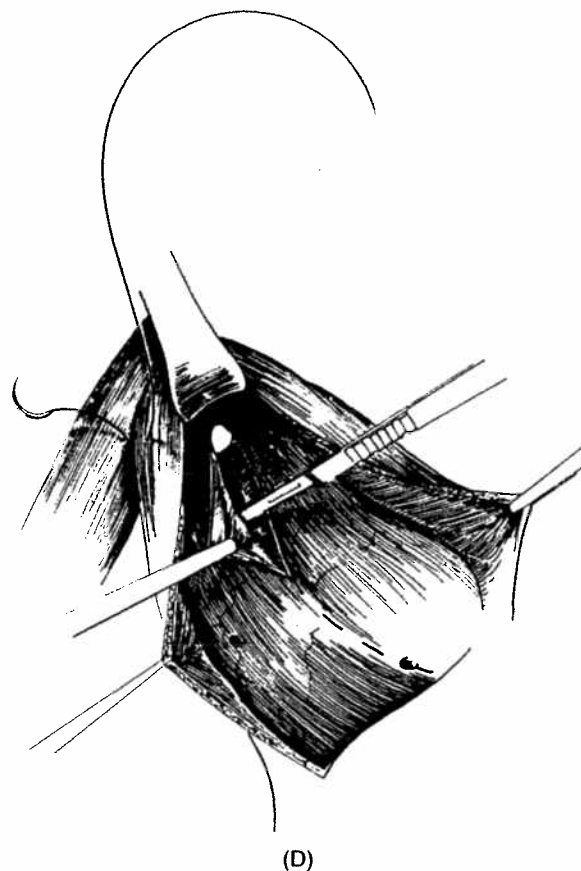
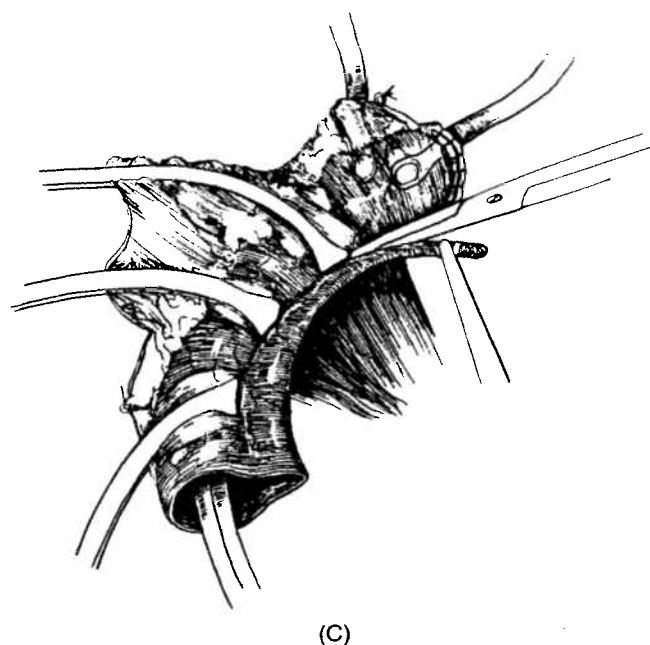


FIGURE 80-22. Tapered intestinal ureter (A-E): Hendren's technique. Despite meticulous technique, persistent reflux is common and late strictures occur.

FIGURE 80-22 *continued*.

reservoir function. Obstruction of the kidney may be caused by acute angulation of the ureter, ischemic contracture, urolithiasis, or inflammatory changes. The need for resectional ureteral tapering, extensive ureteral mobilization, division of the ureter at more than one level, and reconstruction resulting in other than a urothelial-to-urothelial anastomosis appears to enhance this risk.

Ureteral reflux is most commonly encountered because of failure to achieve sufficiently low intravesical (intrareservoir) pressures. Additional risk factors include the employment of nipple valve antireflux techniques as opposed to flap valve techniques.

Bacteriuria is a common finding in patients who undergo major urinary tract reconstruction. This may supply further evidence for those who argue that, at least in children, an antirefluxing attachment of the upper urinary tract to the reservoir is appropriate. When a symptomatic infection occurs, a careful search for an anatomic obstruction, calculus, reflux, or inadequate reservoir compliance/emptying is appropriate.

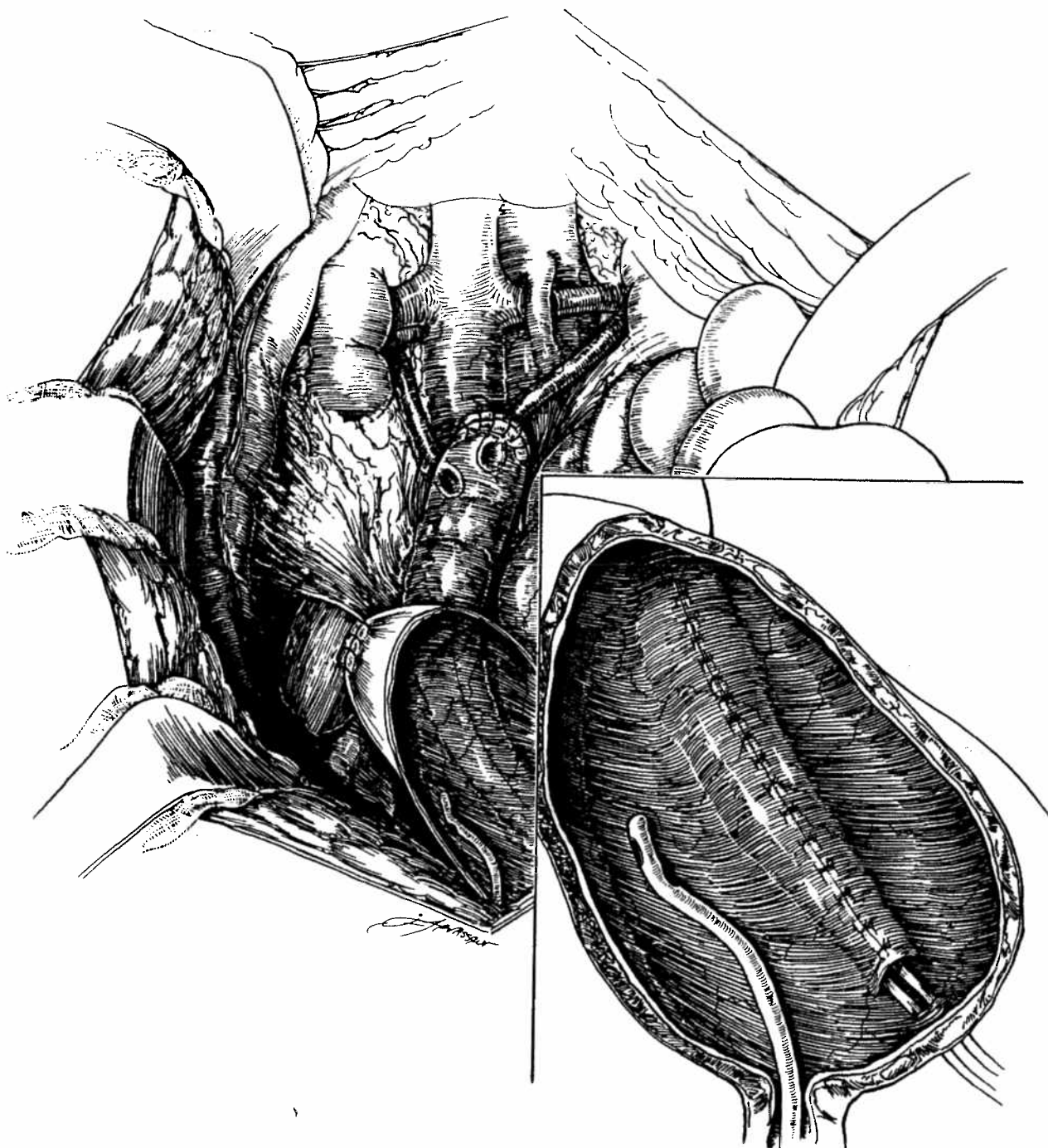
Acute Abdominal Surgical Illness

Acute abdominal surgical illness is a grave concern in the patient who has undergone urinary tract reconstruction, particularly when associated with bladder augmentation or creation of an intestinal reservoir. The most common causes of an acute surgical abdomen in this setting are perforation of the augmented bladder or intestinal reservoir or small-bowel obstruction. Although the etiology remains conjectural, the majority of perforations have been associated with augmentation of a remnant of neurogenic bladder. More than two-thirds of such patients have been on intermittent catheterization and total continence appears to be a common factor. Al-

though the presentation is usually that of an acute abdomen, the symptoms may be quite nonspecific, and a high index of suspicion is essential. It is important to be aware that the rupture may occur many years after reconstruction. Altered sensation in patients with dysraphic states or spinal cord injury, and steroid administration in renal transplant patients may confound the diagnosis. In establishing the diagnosis, a cystogram is essential, but is associated with a significant false-negative rate. A computerized axial tomographic study of the abdomen (with contrast in the bladder or reservoir) may be the most accurate method of making the diagnosis. However, any patient with an augmented bladder on intermittent catheterization who has abdominal pain, fever, or vomiting should be presumed to have a bladder perforation unless the symptoms can be conclusively attributed to another etiology. Exploratory laparotomy may be required to make the diagnosis.

Less common, but important, members of the differential diagnosis include small-bowel obstruction, pseudomembranous enterocolitis, toxic shock syndrome, and ventricular-peritoneal shunt complications.

The performance of laparotomy following urinary tract reconstruction is of critical concern. Certainly, elective laparotomy should be preceded by formal bowel preparation in the face of augmentation or continent diversion. The surgeon should have access to a catheter in the bladder to allow insufflation and desufflation for identification purposes, and a catheter should be placed in any catheterization conduit, such as a Mitrofanoff neourethra. Efforts must be directed at identification and preservation of mesenteric blood supply to any gastric or intestinal segments employed in reconstruction. Whenever possible, an experienced reconstructive urologist should be present.



(E)

FIGURE 80-22 *continued*.

Urolithiasis

In patients with augmented bladders or continent intestinal reservoirs, the development of reservoir or bladder stones (often a number of years after the procedure) is fairly common. The most successful therapies have been found to be extracorporeal shock wave lithotripsy (for upper-tract stones) and open surgical extraction (for reservoir stones). The increased risk of urolithiasis in patients undergoing Mitrofanoff reconstructions may be a result of the loss of dependent drainage of the bladder, resulting in accumulation of mucus and other particulate debris. In our series of 23 consecutive

gastrocystoplasties, we did not encounter any instance of reservoir calculus; this may be because of acidification of urine by the gastric patch.

Metabolic Complications

The multiple and potentially devastating metabolic consequences of employing gastrointestinal segments in the urinary tract were recently reviewed. These metabolic derangements are caused by solute flux (both active and passive) between the urine and blood across the gastrointestinal segment wall. The character and severity

of such derangements are dependent upon the nature of the segment employed, the absorptive surface area, the dwell time, and the metabolic reserve of the individual patient. Compensatory mechanisms for metabolic changes are provided by the kidneys, liver, and lungs. Significant compromise of function of any of these organ systems may exacerbate an underlying metabolic defect. Syndromes include alterations in acid-base status, disorders of serum electrolyte composition, hyperammonemia, and bone demineralization.

Systemic acidosis may result from the incorporation of jejunal, ileal, or colonic segments into the urinary tract. Jejunal conduits are associated with hyponatremia, hyponatremia, hyperkalemia, and acidosis in 20% to 40% of instances. In the jejunum, passive diffusion of solutes occur along their concentration gradients. The passage of hypertonic urine into a jejunal segment will result in a loss of sodium, chloride and water, resulting in hyponatremia, hyponatremia, and volume contraction, with subsequent contraction acidosis. Additionally, diminished renal blood flow results in secondary hyperaldosteronism, resulting in a more hypertonic urine and hyperkalemia. The latter is further aggravated by the potassium shift as a result of acidosis.

The metabolic consequences of interposing ileal and colonic segments within the urinary tract relate to the active secretion of sodium (in exchange for hydrogen) and bicarbonate (in exchange for chloride), as well as the reabsorption of ammonium, hydrogen, and chloride. Ammonium absorption appears to be quantitatively the most important, explaining many of the abnormalities encountered when ileal or colonic segments have an interface with urine. Hydrogen ion, generated from ammonium, is buffered by serum bicarbonate producing water and CO_2 . The latter is readily eliminated by the lungs, resulting in a chronic compensatory respiratory alkalosis. Additional buffering is provided by bone, resulting in a variable degree of demineralization and secondary hyperparathyroidism. This is manifested by hypercalciuria, hyperphosphaturia, hyperoxaluria, hypocitraturia, hypocalcemia, and hypomagnesemia. Osmotic diuresis and acidosis combine to result in total-body potassium depletion. Of great concern is the recent observation that the conventional measurement of serum electrolytes alone fails to detect many cases of absorptive acidosis.

Ureterosigmoidostomy places the patient at risk for the development of hyperchloremic metabolic acidosis. This is particularly problematic because of the massive surface area and the tendency for prolonged periods between evacuation.

Metabolic alkalosis is a unique complication of gastrocystoplasty. Although uncommon, hypokalemic-hypochloremic metabolic alkalosis has been reported. Excessive bicarbonate absorption is postulated to occur secondary to the combination of mineralocorticoid excess and potassium/chloride depletion.

Hypokalemia, hypocalcemia, and hypomagnesemia are significant potential sequelae of incorporating intestinal segments within the urinary tract. Sufficiently severe hypokalemia that results in muscular paralysis has been reported.

While hypocalcemia is rarely severe enough to be symptomatic, it may present with irritability, tremors, tetany, or coma, and may even prove fatal. Hypomagnesemia is also rarely severe enough to be symptomatic but may present with altered sensorium, personality changes, delirium, psychosis, weakness, tremors, tetany, or seizures, and may also be fatal.

Hyperammonemia complicating urinary tract reconstruction with intestine may cause altered sensoria and coma. As previously noted, ammonium ions are actively absorbed from intestinal segments and may be present in large amounts in urine because of

its generation by renal tubules and production from urea by urea-splitting organisms.

The overriding concern of incorporating intestinal segments is the effect on childhood growth and development. Several studies provide data strongly suggestive of defective linear growth in such cases. This concern is particularly worrisome in those patients with diminished renal function. Here, the metabolic insult is more likely and more severe because growth and development are often already significantly impaired.

Strong evidence exists for a primary effect of incorporating intestinal segments into the urinary tract on bone mineralization. Metabolic acidosis results in defects in bone mineralization, bone disease, and linear growth failure through decreased renal tubular calcium reabsorption, depressed intestinal absorption of calcium and phosphorous, and vitamin D metabolism. Treatment with alkalinizing agents has been partially successful in preventing or reversing demineralization disease both experimentally and in patients with urinary intestinal diversion.

Malignancy

A majority of our understanding of urointestinal malignancy following reconstruction comes from the experience with ureterosigmoidostomy. Although the risk of neoplasia in this population is clearly much greater than in the general population, the exact risk has been somewhat difficult to quantitate. There is a substantial interval between the performance of ureterosigmoidostomy and the presentation of malignancy (Fig. 80-23). The mean interval is 24 years, with malignancy being detected in 69% of patients 15 to 30 years following reconstruction. This latency interval has several

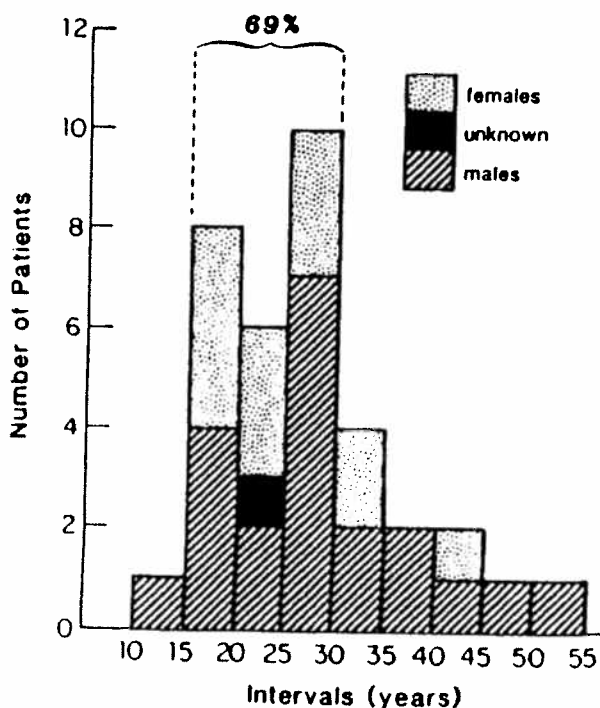


FIGURE 80-23. Interval between ureterosigmoidostomy and diagnosis of malignancy. (From Sheldon CA, McKinley RD, Hartig PR, Gonzalez R. Carcinoma at the site of ureterosigmoidostomy. *Dis Colon Rectum* 1983;26:58. Used with permission).

important implications; a carcinogenic effect is clearly implied. Moreover, there is a potential for early surveillance diagnosis and, clearly, long-term follow-up is mandatory. Importantly, these data raise a concern as to the risk of malignancy with newer modalities of reconstruction for which follow-up is much shorter. Of particular concern to the reconstructive surgeon is the observation of malignancy developing at the site of ureteral stumps years after ureterosigmoidostomy defunctionalization by either nephrectomy or alternate diversion. Patients with previous ureterosigmoidostomy who undergo subsequent reconstruction should have the region of the ureterocolonic anastomoses resected (irrespective of endoscopic appearance) at the time of surgery.

The incidence of malignancy developing in conduits and continent diversion has been comparably small. Of interest, is the observation that exclusion of urine or feces from the urointestinal anastomosis has a protective influence. Additionally, the placement of an interposed segment of intestine between the urointestinal anastomosis and the fecal stream is protective.

Hematuria-Dysuria Syndrome

An important complication of bladder reconstruction using stomach is the hematuria-dysuria syndrome. This is a syndrome of severe pain and urinary bleeding caused by urothelial erosion from acid secreted in the urine following gastrocystoplasty. Endoscopic evaluation of children with the hematuria-dysuria syndrome suggests greater involvement of the urethra than the bladder itself.

Three major factors appear to be of importance in the genesis of this complication: acid hypersecretion, profound oliguria, and bladder-neck incompetency. True acid hypersecretion appears to be quite rare and, presumably, the predominant mechanism for this is hypergastrinemia, which has been reported in some instances.

Altered Gastrointestinal Function

Finally, the incorporation of intestinal segments into the urinary tract may result in significant alterations in gastrointestinal tract function. Alterations in gastric function have been reported following gastrocystoplasty. Functional alterations reported include weight loss, feeding intolerance, dumping syndrome, delayed gastric emptying, and esophagitis.

A review of gastrocystoplasty with emphasis on long-term follow-up (minimum follow-up of 1.5 years) failed to demonstrate any significant incidence of altered gastric function or altered acid base status in 23 consecutive patients. Technical emphasis must be placed on avoiding the vagus nerves, avoiding significant dissection in the region of the gastric pylorus, and avoiding traction-distortion of the angle of His (eg, by gastrostomy tube) that may predispose to gastroesophageal junction incompetence.

Another theoretical concern is the potential for removing sufficient parietal cell mass to interfere with vitamin B₁₂ absorption secondary to decreased intrinsic factor production. Long-term follow-up is necessary to make this determination.

Several potentially important sequelae of intestinal malabsorption may accompany intestinal resection. These include diarrhea, vitamin deficiency, and fecal incontinence. Diarrhea is most frequently caused by alterations in bacterial colonization and impairment of bile acid reabsorption (with or without accompanying steatorrhea).

Malabsorption from ileal resection is directly related to the length of resection. Resections of greater than 100 cm of ileum

(adult equivalent) diminish bile acid reabsorption to a degree that cannot be compensated by increased hepatic synthesis. As a result, the bile salt pool is diminished and steatorrhea develops. Another important sequelae of the diminished bile salt pool in this population is cholelithiasis, which, like urolithiasis, is clinically seen at a significantly increased incidence following ileal resection. Diarrhea induced by altered bile acid reabsorption (with or without accompanying steatorrhea) is further enhanced by the rapid emptying of ileal contents into the colon, causing a tendency for osmotic diarrhea.

The ileum is also the sole site of vitamin B₁₂ absorption and ileal resection is associated with vitamin B₁₂ deficiency. This deficiency is manifested by macrocytic anemia and spinocerebellar degenerative disease, but may take many years to become manifest because of the body stores of vitamin B₁₂.

Although most of the data involves adult patients, it is estimated that 10% of children undergoing resection of ileocecal valve segments will experience chronic diarrhea. This may be resolved after restoring intestinal continuity by returning the ileocecal segment to its normal position within the gastrointestinal tract.

Despite these data, the use of intestinal and gastric segments appears to be extremely well tolerated in most children. It would, however, appear prudent to avoid removal of large segments of ileum or removal of the ileocecal valve for purposes of urinary reconstruction, particularly in those already compromised. Such patients would include those with preexisting malabsorption or short-gut syndromes and patients with marginal fecal continence where fecal soilage may become incapacitating by loss of stool consistency. Such patients include those with myelomeningocele and imperforate anus who commonly require urinary tract reconstruction.

SELECTED READINGS

- Adams MC, Mitchell ME, Rink RC. Gastrocystoplasty: An alternative solution to the problem of urologic reconstruction in the severely compromised patient. *J Urol* 1988;140:1152-1156.
- Aliabadi H, Gonzalez R. Success of the artificial urinary sphincter after failed surgery for incontinence. *J Urol* 1990;143:987-990.
- Borzi PA, Bruce J, Gough DC. Continent cutaneous diversions in children: Experience with the Mitrofanoff procedure. *Br J Urol* 1992;70(6):669-673.
- Camey M, Richard F, Botto H. Bladder replacement by ileocystoplasty. King L, Stone AR, Webster GD, eds. In: *Bladder Reconstruction and Continent Urinary Diversion*. Chicago: Year Book Medical Publishers, 1987:336.
- Duckett JW, Lotfi AH. Appendicovesicostomy (and variations) in bladder reconstruction. *J Urol* 1993;149:567-569.
- Dykes EH, Duffy PG, Ransley PG. The use of the Mitrofanoff principle in achieving clean intermittent catheterisation and urinary continence in children. *J Pediatr Surg* 1991;26(5):535-538.
- Elder JS. Periurethral and puboprostatic sling repair for incontinence in patients with myelodysplasia. *J Urol* 1990;144:434-437.
- Elder JS, Snyder HM, Hulbert WC, Duckett JW. Perforation of the augmented bladder in patients undergoing clean intermittent catheterization. *J Urol* 1988;140:1159-1162.
- Fisch M, Wammack R, Hohenfellner R. The sigma-rectum pouch (Mainz pouch II). In: Hohenfellner R, Wammack R, eds. *Continent Urinary Diversion*. Edinburgh: Churchill Livingstone, 1992.
- Ghonim MA. The modified rectal bladder (augmented and valved bladder). In: Hohenfellner R, Wammack R, eds. *Continent Urinary Diversion*. Edinburgh: Churchill Livingstone, 1992.
- Gonzalez R, Nguyen DH, Koleilat N, Sidi AA. Compatibility of enterocystoplasty and the artificial urinary sphincter. *J Urol* 1989;142:502-504.

- Gold BD, Bhoopalani PS, Reifen RM, Horvey E, Marcon MA. Gastrointestinal complications of gastrocystoplasty. *Arch Dis Child* 1992;67:1272-1276.
- Gosalbez R, Woodard JR, Broecker BH, Warshaw B. Metabolic complications of the use of stomach for urinary reconstruction. *J Urol* 1993;150:710-712.
- Hadley HR, Zimmerman PE, Staskin DR, Raz S. Transvaginal needle bladder neck suspension. *Urol Clin North Am* 1985;12:291-303.
- Hendren WH. Urinary tract refunctionalization after long-term diversion. *Ann Surg* 1990;212(4):478-494.
- Hendren WH. Some alternatives to urinary diversion in children. *J Urol* 1978;119:652-660.
- Hendren WH, Hensle TW. Transureteroureterostomy: Experience with 75 cases. *J Urol* 1980;123:826-833.
- Hollowell JG, Ransley PG. Surgical management of incontinence in bladder exstrophy. *Br J Urol* 1991;68:543-548.
- Juniper BM, McLorie GA, Churchill BM, Khany AE, Toi A. Effects of the artificial urinary sphincter on prostatic development and sexual function in pubertal boys with meningomyelocele. *J Urol* 1990;144:438-442.
- Kock NG, Ghoneim M, Lyche K. Replacement of the bladder by the urethral Kock pouch: Functional results, urodynamics, and radiological features. *J Urol* 1989;141:1111-1116.
- Koff SA. Guidelines to determine the size and shape of intestinal segments used for reconstruction. Estimated influence of bowel length and radius on achievement of augmented bladder volume. *J Urol* 1988;140:1150-1151.
- Kramer SA, Kelalis P. Assessment of urinary continence in epispadias: Review of 94 patients. *J Urol* 1982;128:290-293.
- Lapides J, Diokno AC, Silber SJ, Showe BS. Clean intermittent self-catheterization in the treatment of urinary tract disease. *J Urol* 1972;107:458-461.
- Leadbetter GWJ. Surgical reconstruction for complete urinary incontinence: A 10- to 22-year follow-up. *J Urol* 1985;133:205-206.
- Lepor H, Jeffs RD. Primary bladder closure and bladder neck reconstruction in classical bladder exstrophy. *J Urol* 1983;130:1142-1145.
- Light JK, Engelmann UH. Le bag: Total replacement of the bladder using an ileocolonic pouch. *J Urol* 1986;136:27-31.
- Lockhart J, Davies RR, Cox C, McAllister E, Helal M, Figuero TE. The gastroileal pouch: An alternative continent urinary reservoir for patients with short bowel, acidosis and/or extensive pelvic radiation. *J Urol* 1993;150:46-50.
- McDougal WS. Metabolic complications of urinary intestinal diversion. *J Urol* 1992;147:1199-1208.
- McDougal WS, Koch MO, Shands CI, Price RR. Bony demineralization following urinary intestinal diversion. *J Urol* 1988;140:853-855.
- McGuire EJ, Wang C, Usitalo H, Savastano J. Modified pubovaginal sling in girls with myelodysplasia. *J Urol* 1986;135:94-96.
- Mesrobian HG, Kelalis PP, Kramer SA. Long-term follow-up of 103 patients with bladder exstrophy. *J Urol* 1988;139:719-722.
- Mitchell ME, Rink RC. Experience with the artificial urinary sphincter in children and young adults. *J Pediatr Surg* 1983;18(6):700-706.
- Mitrofanoff P. Cystostomie continente trans-appendiculaire dans le traitement des vessies neurologiques. *Chir Pediatr* 1980;21:297-305.
- Montague DK. Evolution of implanted devices for urinary incontinence. *Cleve Clin Q* 1984;51:405-409.
- Mundy AR. A technique for total substitution of the lower urinary tract without the use of a prosthesis. *Br J Urol* 1988;62:334-338.
- Politano VA. Periurethral polytetrafluoroethylene injection for urinary incontinence. *J Urol* 1982;127:439-442.
- Pow-Sang JM, Helal M, Figuero E, Sanford E, Persky L, Lockhart J. Conversion from external appliance or internal urinary diversion to a continent urinary reservoir (Florida pouch I and II): Surgical technique, indications and complications. *J Urol* 1992;147:356-360.
- Reddy P, Lange P, Fraley E. Total bladder replacement using detubularized sigmoid colon: Technique and results. *J Urol* 1991;145:51-55.
- Rowland RG, Bihle R, Mitchell ME. The Indiana continent urinary reservoir. *J Urol* 1987;137:1136-1139.
- Shands CI, McDougal WS, Wright EP. Prevention of cancer at the urothelial enteric anastomotic site. *J Urol* 1989;141:178-181.
- Sheldon CA, Gilbert A. Use of the appendix for urethral reconstruction in children with congenital anomalies of the bladder. *Surgery* 1992;112(4):805-811.
- Sheldon CA, Gilbert A, Wacksman J, Lewis AG. Gastrocystoplasty: Technical and metabolic characteristics of the most versatile childhood bladder augmentation modality. *J Ped Surg* 1995;30:283-287.
- Sheldon CA, McKinley RD, Hartig PR, Gonzales R. Carcinoma at the site of ureterosigmoidostomy. *Dis Colon Rectum* 1983;26:55-58.
- Sheldon CA, Snyder HM. Principles of urinary tract reconstruction. In: Gillenwater JY, et al., eds. *Adult and Pediatric Urology*. St. Louis, MO: Mosby Year Book, 1996:2317.
- Stamey TA. Endoscopic suspension of the vesical neck for urinary incontinence. *Surg Gynecol Obstet* 1973;136:547-554.
- Turner-Warwick R, Worth PHH. The psoas bladder-hitch procedure for the replacement of the lower third of the ureter. *Br J Urol* 1969;41:701-709.
- Wagstaff KE, Woodhouse CJ, Duffy PG, et al. Delayed linear growth in children with enterocystoplasties. *Br J Urol* 1992;69:314-317.
- Wammack R, et al. The Mainz pouch. In: Holtenfeller P, Wammack R, eds. *Continent Urinary Diversion*. Edinburgh: Churchill Livingstone, 1992:131.
- Whitmore WF, Gittes RF. Reconstruction of the urinary tract by cecal and ileocecal cystoplasty: Review of a 15-year experience. *J Urol* 1983;129:494-498.

Gynecologic Concerns in Patients Born with Anorectal Malformations

Lesley Breech, MD

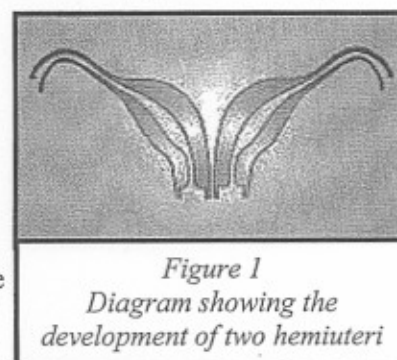
*Assistant Professor Pediatrics, Obstetrics and Gynecology, and Surgery
Cincinnati Children's Hospital Medical Center
Cincinnati, Ohio*

There are several important gynecologic and obstetric concerns that girls and young women with anorectal malformations may have. Unfortunately, at this point in time many unanswered questions remain. We are learning more every day about these issues and with collaboration between patients, families, and providers, we can help subsequent patients by continuously sharing what we've learned. The following is a summary of what we know now.

Does my daughter have a gynecologic anomaly?

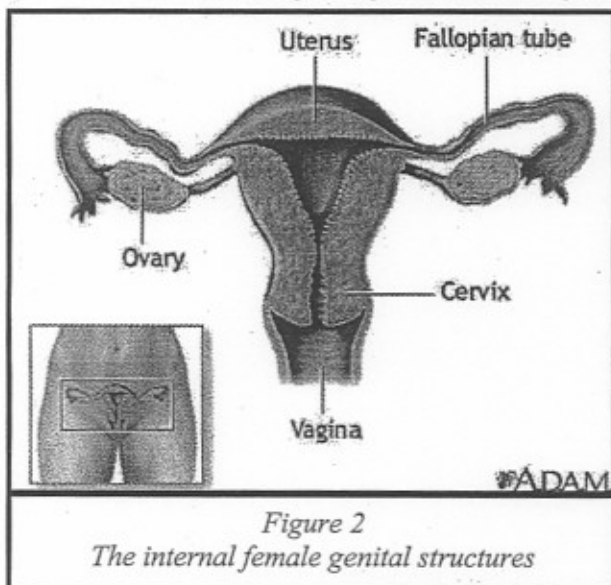
At delivery, determination of gynecologic abnormalities is not urgent because bowel and urologic problems can be serious or even life-threatening. Gynecologic issues may not seem quite as important immediately, yet delineating the reproductive anatomy can be very important to prevent problems in the newborn period or with pubertal development.

Sixty percent of female cloaca patients have some degree of septation, (division or separation) of the uterus and/or the vagina. It can be fairly minimal such as a partial septum or a partial division within the vagina, or it can be much more significant with a duplicated vagina and double uterus and cervix (two hemiuteri). [Figure 1] Genital tract anomalies are less common in conditions such as an imperforate anus with rectoperineal or vestibular fistula. Historically, an assessment of the reproductive structures was not included in the repair of less complex anorectal malformations, so the incidence of reproductive abnormalities may be falsely low. Vaginal septa occur in patients with perineal or vestibular fistula in about three per cent of cases. If identified, the vaginal septum (divider) may be removed during the initial surgery.



*Figure 1
Diagram showing the
development of two hemiuteri*

The internal female structures [Figure 2]: uterus, fallopian tubes, and the upper part of the vagina grow and develop at the same time as the urologic system and gastrointestinal systems. Consequently, any problem in embryologic development in either the urologic or gastrointestinal system could also affect the reproductive system.



*Figure 2
The internal female genital structures*

The Mullerian ducts exist on either side of the embryo and migrate down into the pelvis. The ducts meet in the middle and fuse to form one midline uterus. In patients with an abnormality in development, one hemiuterus with an attached fallopian tube may develop on each side. Canalization occurs to create the central portion of the uterus, the cervical canal, and the vagina. Finally, the endometrium (uterine lining) grows, which completes uterine development. The endometrial lining, which develops each month and sheds as the menses (period), requires an open tract to avoid blockage of flow. At the time of puberty and menarche (the onset of periods), the patency of the reproductive structures should be considered.

Importantly, the ovaries develop from a different embryologic origin than the fallopian tubes, the uterus, and the upper vagina, so they remain unaffected. Hormone production, (estrogen or estradiol) at the time of puberty, as well as the capacity to release the genetic material (the egg) should be normal.

The external genitalia are affected in patients with a cloacal anomaly. Externally, young women with a cloaca will have only one visible opening on the perineum, which is different than the normal female perineum. Normally, each system (urologic, the gynecologic, and the colorectal) exits separately on the perineal skin. The urethra and vagina are located

right next to each other, and the rectum is separated from these by a bridge of skin called the perineal body [Figure 3]. Eventually after surgical separation of all three systems, each opening will be present, a urethra, a vagina, and the rectum/anus. Surgical attempts are made to make the openings and perineum aesthetically pleasing to patients, but since surgery is performed early in life, occasionally some surgical intervention may be necessary later. Discussions about the appearance of the external genitalia are sensitive and require a special relationship between a patient and her pediatric surgeon and gynecologist.

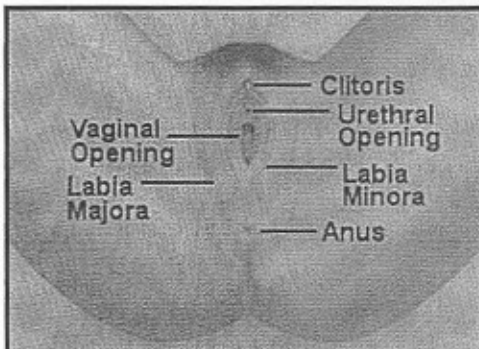


Figure 3

The external female genitalia includes the bridge of tissue called the perineal body which separates the rectum and vagina

In patients with cloacal exstrophy, the pubic bone, mons pubis (a fatty layer overlying the pubic bone), or clitoral area may be more affected. The pubic bones could be separated or there can be atypical development of the mons pubis which increases the likelihood of abnormal development of the clitoris. The clitoris is responsible for the majority of sexual sensation. If clitoral development is impaired, concerns about sensation or the potential for orgasm in the future may exist.

It is imperative to accurately determine the reproductive anatomy. The initial time to accomplish this is during the definitive surgical repair. The reproductive structures can be visualized and the patency confirmed if the surgical repair requires an incision on the abdomen. If, as is the case for the majority of cases, the repair is accomplished exclusively through a posterior sagittal approach (which is through an incision along the buttocks and does not enter the abdominal cavity), a complete assessment is impossible. If the child has a

colostomy, the colostomy closure is the next opportunity to be able to assess the internal gynecologic structures. Later in life an examination under anesthesia of the external perineum and the vagina and cervix (cervix) can be performed with vaginoscopy (a telescope which allows visualization with distension of water).

Gynecological issues to consider may be divided into several categories: 1). Infancy, 2). Puberty, 3). Sexual intimacy, and 4). Obstetrics. (See Table 1). It is easiest to consider the reproductive concerns chronologically in a girl or young woman's life. The major newborn concern is the development of hydrocolpos (which is a very large fluid filled vagina). Menarche or the onset of menstrual periods is the next event with the potential for problems. Sexual intimacy should be discussed after puberty and before the initiation of sexual activity. Lastly, obstetrical issues should also be considered as young women become sexually active and consider childbearing.

Infancy

Hydrocolpos is the collection of fluid within the vaginal space [Figure 4]. Hydrocolpos is more likely to occur in patients with a complex cloacal anomaly. As the vagina fills it can compress the ureter causing hydronephrosis of the kidney which can be dangerous. Drainage of the fluid from the vagina with an indwelling tube until the definitive surgical repair (vaginostomy) is the usual solution to the problem; however sometimes, it may be necessary to drain the urine directly from the urinary system (vesicostomy), bypassing the blockage caused by the distended vagina. Following repair of the cloaca, the rest of early childhood is just like every other little girl's childhood from a gynecologic standpoint.

Puberty and Menarche

At puberty, because the ovaries should be functioning normally, pubertal and breast development should occur as expected. The earliest secondary sexual characteristic in most girls is breast development (thelarche). A 1997 study written by Dr. Herman-Giddens and colleagues from the Pediatric Research in Office Settings Network defined the timing of pubertal development in more than 17,000 healthy young girls in the United States. The mean ages for the onset of breast development were 8.9 years in African-American girls and 10.0 years in white girls. Adrenarche (hair growth) is triggered by the function of the adrenal gland so this also progresses normally. The age of menarche (the first period) has remained relatively stable over the past 20 years at 12.0 to 12.5 years in the US. Therefore a window of opportunity

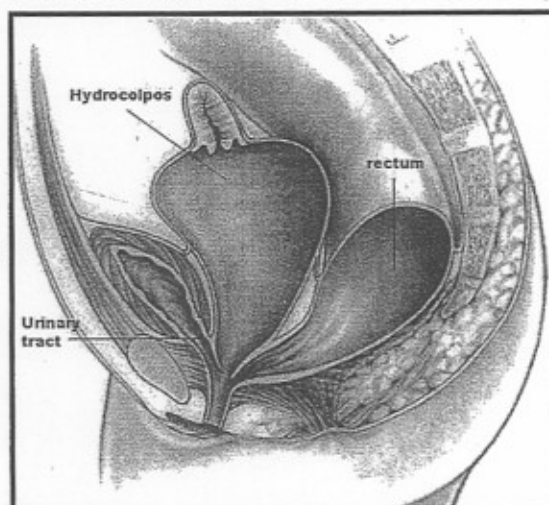


Figure 4

Female infants with a cloacal anomaly can develop hydrocolpos (a collection of fluid within the vagina)

exists to prevent the accumulation of obstructed menstrual fluid if a girl's gynecologic anatomy is not patent (open). Menarche will depend upon several factors and generally occurs 1 – 2 years after the onset of breast development. The time between breast development and the onset of periods is the ideal time for evaluation.

Will my daughter get menstrual periods?

There are several important issues to consider. First, is the consideration that menarche may be influenced by genetic factors. If a young woman with a cloacal anomaly is 15 years old, and has not started periods; her provider may become concerned. However, consideration of the age of menarche of other first degree relatives (mother, sister) may be helpful and reassuring.

Second, the onset of periods relies on the production of hormones by the ovary. Most patients with anorectal malformations, have normally developed ovaries. It is unlikely that the ovaries will have any difficulty producing estrogen. If one ovary was surgically removed, the remaining ovary will take over and make enough hormone for the entire body and release eggs (genetic material). One ovary has enough genetic material to allow children for the future. Sometimes a surgeon or physician may think that ovarian tissue was removed yet there still may be enough of a remnant to produce breast development. A portion of an ovary is all that is necessary. Next, the inner lining of the uterus (endometrium) is stimulated to produce menstrual bleeding. The absence of menses can occur in a significant number of patients with cloacal anomalies due to the absence of a uterus or an under-developed uterus. Many young women may have two under-developed hemi-uteri instead of one fully developed uterus. An under-developed uterus could have very little endometrium or even none at all. If there is no endometrium and only uterine muscle is present, menstrual flow will not occur because the endometrium is what constitutes the menstrual flow. It is very difficult to make this determination until puberty, so it is recommended to undergo an ultrasound of the pelvis within about 6 months after the onset of breast development. This allows determination of whether the lining is beginning to develop or if the lining is present at all seen on ultrasound as a "uterine stripe". Ultrasound is not invasive or painful, so it is an easy way to evaluate the reproductive structures.

Lastly, the patency of the reproductive tract is essential for menstrual blood to drain. The cervix (opening to the uterus) and the vagina must openly communicate to allow flow of the menses. Occasionally there could be a well developed uterus and cervix that appears to be patent; however, if not attached to an open, adequate vagina, obstructive complications may occur. This may manifest as monthly pain on either the right or left side. Optimal communication is established prior to the development of a significant obstruction of menstrual fluid and severe pelvic pain. If adequate vaginal tissue is not available, the cervix and uterus may be attached to a vaginal replacement to allow a patent outflow tract to the skin. Vaginal replacements may be created using a variety of tissue including segments of small bowel, large bowel, rectum, or even skin or bladder. This allows a connection for the menstrual flow and the potential for sexual intercourse. Continued gynecologic follow-up after menarche is important because progressive discomfort or pain with periods (dysmenorrhea) can be suggestive of blockage of only part of the reproductive tract. This could also be demonstrated on pelvic ultrasound or an MRI. Accumulation of menstrual fluid in the obstructed portion of the uterus, tube, or vagina could cause pain and necessitate removal.

If our daughter has two hemi-uteri, will she have two menstrual periods each month?

The ovaries respond to signals from the brain in all females, therefore only one ovary will ovulate (release an egg) and trigger one menstrual period. Both hemiuteri respond to the same signal and the shedding of both endometrium occurs simultaneously. Menstrual periods may be a day or so longer, but otherwise normal. Irregular bleeding after menarche is caused by the same diagnoses as other adolescents without anorectal or reproductive issues.

Is our daughter at risk for any other gynecological problems?

After puberty, young women may develop cysts (fluid collections) in the pelvis. Cysts often occur on one side of the pelvis and may be quite painful. The fluid collections may originate from the an ovary or the lining of the pelvis itself. Hormonal stimulation is felt to play a role in the development of cystic structures. Pelvic cysts are more common in young women after repair of cloacal exstrophy. Hormonal suppression or x-ray guided drainage are the standard treatment for these cysts.

Endometriosis is a gynecologic condition in which the lining of the uterus (endometrium) is found outside the uterus. It is more likely to occur in patients with a history of retrograde (reverse) menstrual flow, as in cases of obstruction to menstrual drainage. Chronic pain and discomfort, in addition to possible effects on fertility, are the major concerns with this condition. Lastly, chronic pelvic pain has also been described and may be attributed to the development of scarring

after numerous surgical procedures.

Sexual Function

Comfortable, satisfying sexual intimacy is a goal for all women. Sensation of the external genitalia is primarily controlled by nerves located in the clitoral region. Clitoral development is usually unaffected in patients with anorectal malformations; sexual satisfaction and orgasm are expected to be normal. Sometimes at the time of the definitive repair the area of the clitoris can be cosmetically optimized. In patients with a complex cloacal anomaly, anatomic positioning of the clitoris and vagina may require physical adjustments for full sexual satisfaction or orgasm with vaginal intercourse.

If vaginal development is incomplete or preservation of the natural vagina cannot be accomplished surgically, a vaginal replacement (neovagina) may be necessary. Goals of creation of a neovagina include the creation of a structure of adequate size and position to accommodate sexual intercourse, the production of a "normal" amount of secretion and lubrication, and the necessity for minimal care for maintenance. Sometimes patients require additional minor outpatient vaginal surgery after puberty to facilitate comfortable intercourse. Even if menses occur without difficulty, the vagina should still be evaluated by a gynecologist familiar with the patient's history and experienced in reconstructive surgical procedures.

The initial surgery is performed to separate the colorectal, urologic, and gynecologic systems, so revision of the vaginal opening at the time of the onset of sexual activity may be indicated. Some patients may desire minor revisions of the anatomic appearance of the external genitalia. Growth and development of the genitalia continues well into puberty, so consideration of possible surgery should be reserved until the completion of puberty. This is possible if it will not influence the function of the area. The goal is a good functional outcome for young women including fecal and urinary continence and a satisfying sexual life. Interaction with a trained, experienced psychologist may also be beneficial when discussing such personal components of sexual life.

Obstetrics

Unless unusual scarring occurs after definitive surgical repair, fertility issues are usually not the primary concern. As previously described, the ovaries, containing the genetic material (eggs), develop normally. Proper communication with the fallopian tube is necessary for fertilization. Adequate development of the uterus, with an endometrial lining, is necessary for implantation of an embryo. Sufficient uterine muscular development is also important to carry a pregnancy to a viable gestational age. The implications of a poorly developed cervix are at present unknown. Limited data is currently available; however, a number of women born with cloacal malformation have delivered healthy babies, even with hemiuteri.

What problems may she be at risk for during pregnancy?

Patients may develop preterm labor or early delivery. Uterine didelphis (two hemiuteri positioned close together) has the best obstetrical outcome of any major congenital uterine anomaly in patients without a cloacal anomaly. It is desirable to apply this data to women who have two hemiuteri with a cloaca; however, it is important to determine if other factors may influence obstetrical outcomes.

If my daughter has two hemi-uteri, is she more likely to have twins?

As in all women, the ovaries respond to the same signal from the brain triggering the release of one egg each month (ovulation). If the egg is fertilized, the embryo will implant in the uterus or one of the hemiuteri. It is the egg release and the fertilization process that determine if a twin pregnancy will develop, so the presence of two hemiuteri will not increase the chance of having twins.

If a patient with an imperforate anus with a rectoperineal or vestibular fistula has been properly repaired, a vaginal delivery may be possible. Examination by an experienced obstetrician-gynecologist (ob-gyn) is important to confirm appropriate anatomic repair and healing of the perineum. With advanced reconstructive surgery, such as in cases of cloacal repair, bladder augmentation, bladder neck reconstruction, or vaginal replacement, a cesarean section may be recommended. Because of the complex nature of the reconstructive procedures performed during infancy, the urologic or gastrointestinal system may be in jeopardy during a cesarean section; therefore, a planned delivery by a multidisciplinary team, including an ob-gyn experienced in pelvic reconstructive surgery, is strongly recommended. The Colorectal Center for Children at Cincinnati Children's Hospital Medical Center works in conjunction with the Fetal Care Center of Cincinnati for the care of such patients and is the only center in the world to offer such advanced specialty care.

Management of Reproductive Structures

Observation

Most girls should have undergone an assessment of the development and patency of the reproductive structures in infancy, either during the definitive surgery or during colostomy closure. In circumstances where the anatomy has not been previously discussed with family, detailed information can be obtained by reviewing previous operative records with the pediatric surgeon or gynecologist. Physical examination in the office or under anesthesia (with vaginoscopy) can provide information regarding the vagina and cervix or the external genitalia. Imaging studies (ultrasound) performed after puberty can also provide helpful information. Occasionally, laparoscopy to look at the reproductive structures may be needed.

Although the American College of Obstetrician and Gynecologists recommends all adolescent females age 13 – 15 years have an initial reproductive health visit, young women with a history of an anorectal malformation should have an earlier visit. This allows a review of normal pubertal development and a discussion regarding possible gynecological issues to expect. An ultrasound of the pelvis within 1 – 2 years of the onset of breast development is also recommended. Serial ultrasounds provide information about the degree of development of the uterus and endometrial lining and can exclude the presence of an obstructed reproductive tract. Even if mildly obstructed structures are diagnosed, medications can be used to suppress hormonal stimulation and prevent continued accumulation of menstrual blood. Such suppression may increase the chance that reproductive structures may be preserved instead of removed.

Removal

If poorly developed reproductive structures are identified as an infant, especially if patency cannot be confirmed or established surgically, the uterus or fallopian tubes may be resected. If significant obstruction and distension with menstrual blood occurs, most reproductive structures will need to be removed. It seems that if one side of the reproductive system is considerably less developed, it is of great risk for obstruction and complications; and thus removal of the abnormal side is recommended.

Reconstruction

From a gynecological standpoint, establishment of adequate communication between the uterus (hemiuteri), vagina, and perineum is the main goal. When the natural vagina is not adequate, a vaginal replacement (neovagina) can allow the proper outflow of menstrual blood and provide an adequate space for vaginal intercourse. Minimizing the risk of an obstruction of the gynecological system remains a priority.

Conclusion

Gynecologic concerns are particularly important at several intervals: infancy, puberty and the onset of menses, the debut of sexual intimacy, and pregnancy. Definition of reproductive anatomy provides the key to appropriate counseling and preparation. We continue to learn more daily as we care for a growing population of young adult women born with anorectal malformations.

Mark Your Calendars!

**UOAA First
National Conference**

August 16-18, 2007

**Lincolnshire Marriott Resort
Chicago, Illinois**

***We're planning a great time for the
entire family—educational sessions
and fun events you don't want to miss!***



RESOURCES

Pull-thru Network

Bonnie McElroy, Executive Director
2312 Savoy St.
Hoover, Alabama 35226-1528
205-978-2930
pullthrunketwork.org

Imperforate Anus Parents Support Group

Yahoo.com : This group is for parents of children born with Imperforate Anus.

Vater/Vacterl Association Groups

TEF/VATER Support Network

15301 Grey Fox Road
Upper Marlboro MD 20772
301-952-6837
E-mail: info@tefvater.org
Web: <http://www.tefvater.org/>

<http://health.groups.yahoo.com/group/VaterAssociation>

<http://www.vacterlnetwork.org>

Other websites

<http://www.bgk.org.au> : Bowel Group for Kids

<http://www.hirschsprungs.info/index.htm> : Hirschsprungs & Motility Disorders Support Network (HMDSN)

<http://www.php.com> : Parents Helping Parents

<http://www.birthdefects.org> : Birth Defect Research for Children, Inc.

<http://www.romacivica.net/aimar/home.html> : Associazione Italiana Malformazioni Ano-Retalli (aimar)

<http://www.soma-ev.de/dt/index.htm> : SOMA

<http://rally4youth.org> : Youth Rally

Steven D. Wexner
Graeme S. Duthie *Editors*

Constipation



Etiology, Evaluation, and Management
Second Edition

 Springer

Steven D. Wexner and Graeme S. Duthie (Eds)

Constipation

Etiology, Evaluation, and Management

Second Edition

Foreword by David C.C. Bartolo, MS, FRCS, FRCSE

 Springer

Surgical Treatment of Hirschsprung's Disease

Alberto Peña and Marc A. Levitt

History

Hirschsprung's disease represents the most common cause of intestinal obstruction in the newborn. The term *Hirschsprung's disease* is used to describe a condition that is a functional colonic obstruction. These patients do not suffer from a real mechanical obstruction but rather from a serious disturbance in the normal colonic peristalsis, due to a lack of ganglion cells. Dr. Harald Hirschsprung¹ presented what is considered a classic description of this condition in the Pediatric Congress in Berlin in 1886. The description, however, referred only to a congenital dilation of the colon, without a real understanding of the histology and pathogenesis.

It was Tittel² in 1901 who mentioned the absence of ganglion cells in the distal colon in a child suffering from this condition. In 1948 Whitehouse and Kernohan³ and Zuelzer and Wilson⁴ documented the absence of ganglion cells in the distal part of the colon. The recognition of aganglionosis in the distal part of the colon as the main cause of the symptoms in these patients led to the rational surgical treatment used presently. Swenson and Bill⁵ described the first rational surgical approach, consisting of the resection of the aganglionic segment and a pull-through of a normoganglionic piece of colon to be connected to the anal canal. Subsequently, different variants to this basic principle were introduced into the literature including the Duhamel approach,⁶⁻⁸ the Rehbein approach in 1959,⁹ the Soave operation,¹⁰ and the Boley modification.¹¹ All of them are actually modifications from the previous approach. More recently, a transanal resection of the aganglionic bowel as well as a

complete transanal pull-through was described by De La Torre and Ortega.¹² During the last few years, laparoscopically assisted techniques have been added to the treatment of this condition.¹³⁻¹⁶

Etiology, Pathophysiology, and Incidence

The absence of ganglion cells in the submucosa (Meissner plexus) and intermuscularly (Auerbach plexus) in the distal intestine, as well as a marked increase in nerve fibers that extend into the submucosa, seemed to be the hallmark of this condition. There is also an increase in the activity of acetylcholinesterase.¹⁷⁻²² The lack of ganglion cells affects the most distal part of the rectosigmoid in about 80% of the cases, which represent the so-called typical cases of Hirschsprung's disease.^{23,24} The extension of the aganglionosis varies. It may reach the descending colon as well as the splenic flexure and part of the transverse colon, which is called "long segment Hirschsprung's disease."²⁵ It may affect the entire colon, which is called "total colonic aganglionosis,"^{26,27} and there are reports in the literature of patients with a universal aganglionosis (total intestinal aganglionosis), a condition that so far has been incompatible with life.²⁸

There is also a rather controversial condition called "ultrashort" Hirschsprung's disease.²⁹ In this condition, the aganglionic segment supposedly measures only a few centimeters and is located immediately above the anal canal. Not everyone agrees with the existence of this condition because normal individuals have an

area of aganglionosis in the distal few centimeters of the rectum.

The aganglionic segment of the colon is never distended; however, proximal to this affected bowel, there is enlargement of the colon (megacolon). In between the aganglionic, nondistended, and normoganglionic megacolon, there is a transition zone in which there is a decreased number of ganglion cells (hypoganglionosis). The aganglionic portion of the colon most probably represents an area with lack of continuity of the peristalsis, which translates into a functional obstruction. There is accumulation of fecal matter proximal to the aganglionosis. This has also been referred to as "lack of relaxation" of the distal aganglionic segment. In the area of absent ganglion cells, there is a marked increase in the innervation provided by the extrinsic nervous system. The aganglionic colon is conceived as a permanently contracted piece of bowel interfering with a normal peristalsis.

There is a conspicuous absence of nitric oxide synthase in the myenteric plexus of the aganglionic tissue.³⁰⁻³² Although the pathophysiology of Hirschsprung's disease is still a matter of mystery, it is much more than just a functional colonic obstruction. The fecal stasis that occurs in the proximal normoganglionic bowel does not produce just a fecal impaction, as in cases of idiopathic constipation. These patients suffer from other not well-understood aggravating functional abnormalities that may explain other more serious symptoms. The fecal stasis leads to bacterial overgrowth, which produces an explosive type of diarrhea, abdominal distention, fever, and a very serious toxic condition. An inflammatory infiltrate of the intestinal mucosa occurs and eventually, the mucosa becomes ulcerated. The bacteria can then traverse the intestinal epithelium, and abnormal bacteria proliferate, particularly *Clostridium difficile*. This condition is called "enterocolitis" and may occur from the very few hours after the baby is born before surgery or even after a successful operation. There are many unknown factors contributing to this serious and mysterious condition in which the babies become extremely sick. They suffer from a state of endotoxemia and die if not aggressively and effectively treated.³³⁻³⁶ It seems likely that the local immune system is also abnormal in these children, as well as the characteristics of the mucus of the bowel.^{39,40}

The incidence of Hirschsprung's disease has been reported to be 1 in 4000 to 1 in 7000.^{41,42}

There is a definite male preponderance except for the long segment type of Hirschsprung's, in which the ratio seems to be 1:1 male to female.⁴³ Male patients with long-segment Hirschsprung's disease and sons of affected females have a 24% chance of being affected.⁴⁴

Clinical Manifestations

Traditionally, Hirschsprung's disease was suspected in children who suffered from constipation. However, progressively, over the last several decades, the index of suspicions for this condition increased, which has allowed the recognition of this disease earlier in life.

In the United States today, it is rather unusual to find an undiagnosed patient with this condition at school age. The most common manifestation of Hirschsprung's disease during the newborn period is the lack of passage of meconium during the first 24 hours. When a baby does not pass meconium during that period, it should be considered highly suspicious for Hirschsprung's disease. Subsequently, the abdomen becomes distended and the baby vomits. The symptoms progress as in any other case of colonic obstruction because the baby looks toxic, lethargic, dehydrated, and septic. Rectal stimulation either with a thermometer or with a finger provokes characteristic explosive bowel movements, followed by the passing of large amount of fetid gas, all of which gives the baby temporary relief, but a few hours later the symptoms recur. A small percentage of patients may survive without medical help; over time, they develop clinical signs of severe constipation, abdominal distention, and failure to thrive.

Hirschsprung's disease during the newborn period should be differentiated from other causes of colonic obstruction such as imperforate anus. Imperforate anus is easily diagnosed by a simple inspection of the perineum. A very unusual condition is atresia of the colon; this very rare defect produces enormous dilatation of the proximal colon. Since the distal colon is not developed, and a severe microcolon is demonstrated with contrast study through the rectum. Meconium ileus may also simulate the clinical picture of Hirschsprung's disease, but this condition has characteristic features; all these babies suffer from cystic fibrosis that can be easily diagnosed at this stage by a sweat test, and radiologically, the inspissated meconium shows a

characteristic pattern described as "ground-glass image" located in the lower abdomen.

Untreated patients with Hirschsprung's disease who survive and reach school age suffer from severe megacolon. These patients must be differentiated from patients with idiopathic constipation. Patients with Hirschsprung's disease have a large amount of stool located in the very dilated proximal colon. However, the distal, aganglionic segment is usually empty of stool. Patients with severe idiopathic constipation have a megarectum and fecal impaction located all the way down in the area of the anal canal. The finger of an examiner will perceive the presence of a huge fecal impaction located very low in the pelvis, while patients with Hirschsprung's disease are described as having an empty rectum. Patients with Hirschsprung's disease characteristically do not soil their underwear. Again, it is very unusual to see patients with Hirschsprung's disease at this age. Survivors in fact represent a very small percentage of all Hirschsprung's patients. A majority of undiagnosed patients die in the early stages of the condition when they go untreated.

Diagnosis

A high index of suspicion is the most important element for the early diagnosis and treatment of this condition. An abdominal plain film shows very dilated loops of bowel. Unfortunately, during the newborn period, it is extremely difficult, on a plain abdominal film, to differentiate small bowel from large bowel. These babies have a dilated colon, proximal to the aganglionic portion.

When babies are born with Hirschsprung's disease, they still do not develop a severe degree of megacolon. As time goes by, the colon, proximal to the aganglionic segment, becomes more and more dilated, showing dramatic contrast with the undilated distal bowel and the transition zone. The clinician should not expect to find a conspicuous megacolon with a distal narrow segment in the newborn.

A contrast enema is extremely important for the diagnosis of this condition. This study does not demonstrate a transition zone in 100% of cases, but its value varies from institution to institution and depends very much on the experience of the observer.⁴⁵⁻⁴⁷ A positive contrast study shows a nondilated distal portion followed

by a dilated proximal aganglionic segment. Sometimes the diagnosis is very obvious and sometimes, for unknown reasons, the transition between dilated and nondilated colon is not so well demarcated. In patients with total colonic aganglionosis, the entire colon is nondilated and the main dilatation of the bowel affects the small bowel.

The contrast study in these babies must be performed by an experienced pediatric radiologist. A catheter is introduced through the rectum not more than 4 cm. Passing the catheter more than necessary will result in the injection of the contrast material directly into the dilated portion of the colon, bypassing the nondilated portion as well as the transition zone, and therefore precluding making the diagnosis. Failing to pass the contrast material in the 24 hours following the study is considered highly suggestive of the diagnosis of Hirschsprung's disease.

Occasionally, an unattended baby may suffer from a bowel perforation; the perforation is usually located in the cecum. These patients require emergent surgery. The presence of a perforation in the cecum raises the likelihood of Hirschsprung's disease.

Anorectal Manometry

The inflation of a balloon in the rectum in a normal individual produces decreased anal canal pressure called the "anorectal reflex" and is present in all normal individuals. Anorectal manometry in children with symptoms suggestive of Hirschsprung's disease is performed with the goal of eliciting such a reflex. A lack of relaxation of the anal canal is considered diagnostic of Hirschsprung's disease.⁴⁸⁻⁵³ However, there is a significant degree of controversy about the value of this diagnostic test, and most pediatric centers and surgeons do not use this diagnostic modality.

Rectal Biopsy

A rectal biopsy represents the definitive diagnostic test in children with Hirschsprung's disease. It requires, however, interpretation by an experienced pediatric pathologist. Most surgeons and pediatric centers use a suction rectal biopsy for the diagnosis of this condition.⁵⁴⁻⁵⁷ This biopsy can be performed at the bedside and

is considered highly diagnostic, again provided that the pediatric pathologist is experienced with the interpretation of this kind of biopsy. One of the limitations of this type of procedure is that often the specimen does not include the submucosa and therefore is not adequate for an accurate diagnosis. Another limitation is performing the biopsy too distal in the rectum where supposedly there is a normal area absent of ganglion cells.⁵⁸ A suction rectal biopsy, however, only makes the diagnosis of aganglionosis but does not determine the length of the abnormality.

Although a full-thickness rectal biopsy provides a much better specimen, it must be done under anesthesia.⁵⁹ This biopsy is still done in institutions where the pathologist is not familiar with the diagnosis of Hirschsprung's with a suction biopsy or in institutions where the surgeons do not have the suction biopsy device to perform such a procedure. An increase in the activity of acetylcholinesterase is also considered diagnostic,^{55,56} but not all pathologists rely on this analysis.

Treatment

The newborn baby suffering from abdominal distention, vomiting, dehydration, or explosive fetid bowel movements, or who looks toxic and lethargic, needs emergency management. Intravenous fluids, antibiotics, and most importantly, rectal irrigations must be promptly started.

Little is known about the pathophysiology of this potentially lethal enterocolitis. However, stasis seems to be the most important predisposing factor and therefore these babies will dramatically improve by decompressing the colon, which can be done on a temporary basis by passing a rectal tube. Sometimes the characteristics of the meconium and the fecal matter may interfere with the drainage of gas and liquid from the colon through the tube. Therefore, the lumen of the tube should be cleared by the infusion of small amounts of saline solution, and the tube must be moved back and forth. This maneuver produces a spectacular decompression of the colon with dramatic improvement of the patient's symptoms. However, this temporary measure cannot be considered adequate long-term treatment because a few hours after the

decompression the baby will start to become distended again and the symptoms will recur. Regardless of their transient benefit, rectal irrigations are still considered extremely valuable; they maintain the baby in good condition until a more permanent type of treatment is indicated. Sometimes the babies are so sick that one cannot consider performing a contrast enema because of the risk of perforation. The rectal irrigations, antibiotics, and intravenous fluids may return the baby to a better clinical condition in order to perform other diagnostic and therapeutic procedures. When the baby recovers from the acute state of enterocolitis, the rectal biopsy is performed, establishing the definitive diagnosis.

Traditionally, patients with Hirschsprung's disease were treated in three stages. The first stage consisted of opening a diverting colostomy, which decompressed the colon; it allowed the baby to recover and be discharged. Most surgeons open a colostomy in the right transverse colon or establish an ileostomy in babies with total colonic aganglionosis. The second stage consists of resection of the aganglionic segment and pull-through of the normoganglionic bowel to be anastomosed to the anal canal with the technique of preference for the specific surgeon. The third stage consists of closure of the colostomy after the baby recovers completely from the main pull-through procedure. This three-stage approach is now considered rather historical.

Subsequently, surgeons trying to avoid surgical trauma to the babies devised a two-stage type of repair. In the first operation, a colostomy was created immediately proximal to the transition zone, which is called a "leveled colostomy." In the second and definitive stage, the surgeons performed the pull-through, pulling down what used to be the colostomy into the anal canal and leaving the patient without a protective colostomy.

Finally, the most recent approach involves performing the main pull-through during the first few days, weeks, or months of life, as a primary procedure without a protective colostomy.⁶⁰⁻⁶³ This approach avoids two operations for the baby (colostomy opening and colostomy closure) and has been demonstrated to be feasible without adding extra morbidity to the patient. However, a colostomy is still an extremely valuable operation for babies with Hirschsprung's disease under special

circumstances. For instance, a very sick baby suffering from other aggravating factors or enterocolitis could still be a candidate for this kind of preliminary procedure. In general, most surgeons take these babies to the operating room for a pull-through with a plan for a colostomy if necessary. When the technical circumstances of a pull-through are not satisfactory and the surgeons have doubts about the viability of the pull-through bowel in terms of blood supply or any other kind of technical difficulties, they can always protect the pull-through with a proximal colostomy. Also, in hospitals, cities, or countries where the surrounding circumstances for the baby, as well as the infrastructure, are not adequate, a surgeon can save the baby's life with a colostomy.

To perform the primary neonatal pull-through, one should expect to have a newborn baby in excellent clinical condition with a completely decompressed colon, typically over several days. The patients receive parenteral nutrition and undergo colonic irrigations.

Main Repair

Swenson Procedure

This procedure has the merit of being the first rationally designed surgery to treat this condition.⁵ It was used for many years by Dr. Swenson himself.²³ A few surgeons in the world still perform the original Swenson operation.^{64,65} For this kind of pull-through operation, the patient must be prepared so that the surgeon can approach the abdomen as well as the perineum. Basically, the entire body, below the rib cage is prepared in the usual manner so that the surgeon can approach the abdomen or the perineum several times either by turning the patient from supine into prone position or simply by lifting up the legs to approach the perineum and then down to approach the abdomen. Transabdominally, the aganglionic portion of the colon is resected including the most dilated portion of the bowel (Fig. 24.1A). In a case of typical Hirschsprung's disease, only the splenic flexure

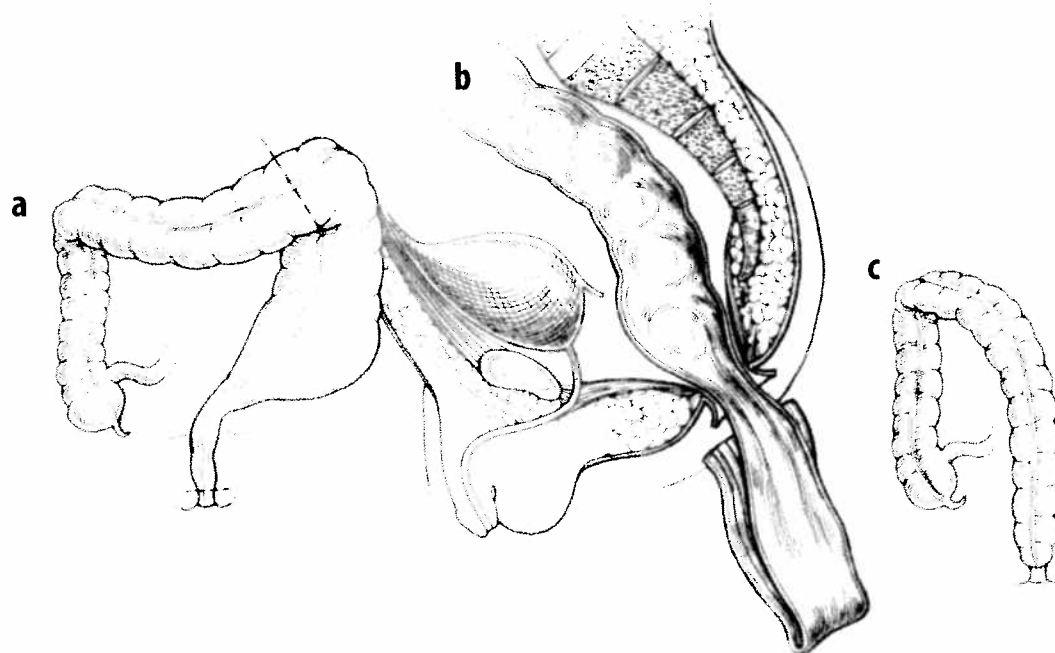


Figure 24.1. The Swenson surgical technique. a: Resection of the aganglionic and dilated bowel. b: Pull-through of normal ganglionic bowel. c: Operation finished. From Peña A. Surgical treatment of Hirschsprung's disease. In: Wexner SD, Bartolo DCC, eds. Constipation: Etiology, Evaluation and Management. New York: Butterworth-Heinemann, 1995:168–175, reproduced by permission of Edward Arnold.

must be mobilized. Conversely, dealing with a long segment type of disease, it may be necessary to mobilize the right colon to obtain adequate length for the pull-through. The aganglionic portion of the colon below the peritoneal floor is dissected in a very precise manner, staying as close as possible to the rectal wall down to the level of the levator ani muscle. Dissection of the rectum includes the ligation of the middle hemorrhoidal vessels and the use of cautery to the perirectal vasculature (Fig. 24.1). Special care is taken to preserve the anal canal, above the pectinate line. The aganglionic segment of the colon is resected and the new, normoganglionic colon is pulled through (Fig. 24.1B,C) the same space in the pelvis and anastomosed by a conventional, transanal, hand-sewn technique. The basic principles of this procedure are still observed in most modern operations. Swenson developed extraordinary experience with this operation and he and his followers claimed good results.^{64,65} Despite these reports, some patients operated on by other surgeons were reported to suffer signs and symptoms related to damage of important nerve structures in the pelvis. Because of nerve injury, other procedures were designed, with the specific purpose of avoiding nerve damage in the pelvis. Such procedures were created by Duhamel and Soave.

Duhamel Procedure

Duhamel⁶⁻⁸ designed his procedure with the specific purpose of avoiding extensive pelvic dissection. This avoidance is reportedly accomplished by preserving the pelvic portion of the aganglionic rectum, dividing the bowel at the peritoneal reflection as distally as possible (Fig. 24.2A). The aganglionic rectal stump is then closed. The normoganglionic bowel is pulled down directly in front of the sacrum in a safe space behind the rectum that is created by blunt dissection (Fig. 24.2B). Lateral dissection is therefore avoided, which prevents nerve damage. The posterior rectal wall is incised above the dentate line, entering the previously dissected retrorectal space. The normoganglionic bowel is pulled through the rectal incision in the posterior wall of the rectum and a GIA stapler or (in the past) two large crushing clamps are used to create an anastomosis between the aganglionic rectum and the normoganglionic pulled-down

bowel (Fig. 24.2C-F). The anastomosis between the pulled-through colon and the aganglionic rectum is created as wide as possible, and the rectal stump must be as small as possible in order to avoid fecal accumulation (Fig. 24.2G).

This procedure still has many followers all over the world;²⁴ it is a very appealing operation because it is easy and technically reproducible. The problem with this operation is that the portion of rectum that is aganglionic still suffers from the same dysmotility disorder of the primary Hirschsprung's condition. As a consequence, these patients tend to accumulate stool into that rectal stump and return for follow-up with a hypertrophic aganglionic rectum with fecal impaction. Many require reoperation to remove the aganglionic portion and create an end-to-end anastomosis as in Swenson's operation.

Soave Procedure

Franco Soave,¹⁰ an Italian surgeon, created this ingenious and appealing operation, with the specific theoretical purpose of avoiding the consequences of nerve damage provoked by an imprecise Swenson dissection. The aganglionic rectosigmoid is resected by an endorectal dissection, theoretically minimizing the risk of pelvic injury (Fig. 24.3A,B).

The normoganglionic colon is passed through the rectal muscular cuff left after the endorectal dissection (Fig. 24.3C,D). There is no aganglionic segment of rectum left, such as that left with the Duhamel procedure. This operation is less reproducible than the Duhamel procedure and requires meticulous technique in the dissection of the mucosa from the muscular cuff. The endorectal dissection is performed immediately around the mucosal layer and inside the smooth muscle layer of the bowel (Fig. 24.3C). This dissection is usually initiated 1 or 2 cm above the peritoneal reflection. It is carried down to a point about 1 cm above the pectinate line in order to preserve the anal canal with its sphincteric mechanism and sensation. The normoganglionic colon is anastomosed to the anal canal about 1 cm above the pectinate line (Fig. 24.3D). Soave originally performed this operation without a colostomy, leaving a portion of the pulled-through colon protruding well beyond the anal skin margin. About a week later, this portion of the bowel was resected and an anastomosis was created between the normoganglionic bowel

Figure 24.2
through c
through t
operation
Butterworth

ween
lionic
d the
le in
2G).
lover
ation
cible.
t the
ffers
the
onse-
stool
w-up
fecal
nove
-end

this
the
the
y an
onic
dis-
k of

ough
ectal
onic
with
less
and
tion
The
itely
both
This
rove
to a
rder
eric
onic
cm
rig-
t a
led-
mal
r of
was
wel

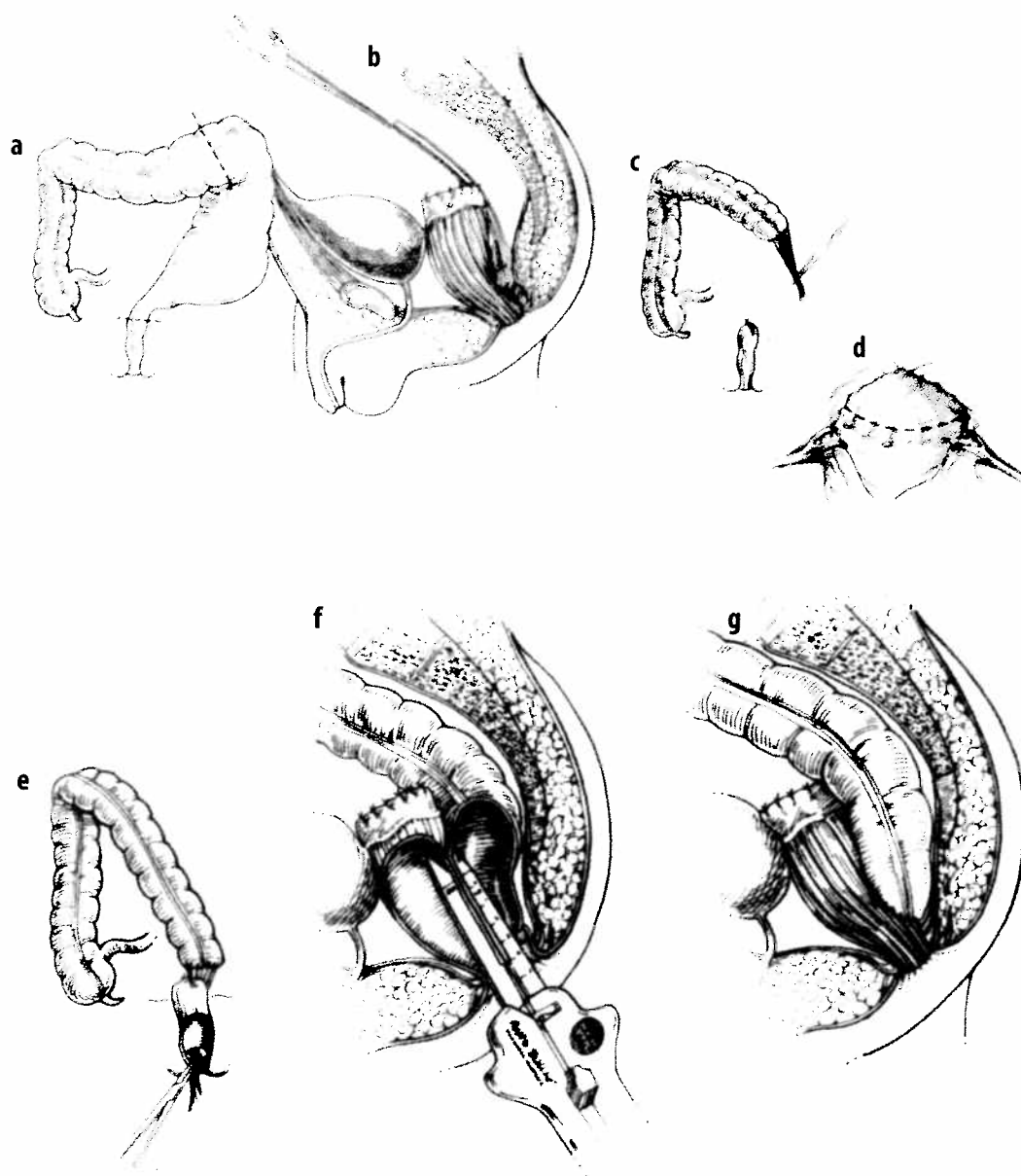


Figure 24.2. Duhamel technique. a: Resection of the dilated portion and part of the aganglionic segment. b: Presacral, retrorectal dissection. c: Pull-through of normal ganglionic bowel. d: Incision of the posterior rectal wall, above the pectinate line. e: Pull through of normal aganglionic colon through the window in the posterior rectal wall. f: Creating a wide anastomosis between normal ganglionic and aganglionic segment. g: Finished operation. From Peña A. Surgical treatment of Hirschsprung's disease. In: Wexner SD, Bartolo DCC, eds. Constipation: Etiology, Evaluation and Management. New York: Butterworth-Heinemann, 1995:168-175, reproduced by permission of Edward Arnold.

Trans

More re
a simpl
this co
animals
moid c
fashion
agangli
down t
most co
(the so
gliconic

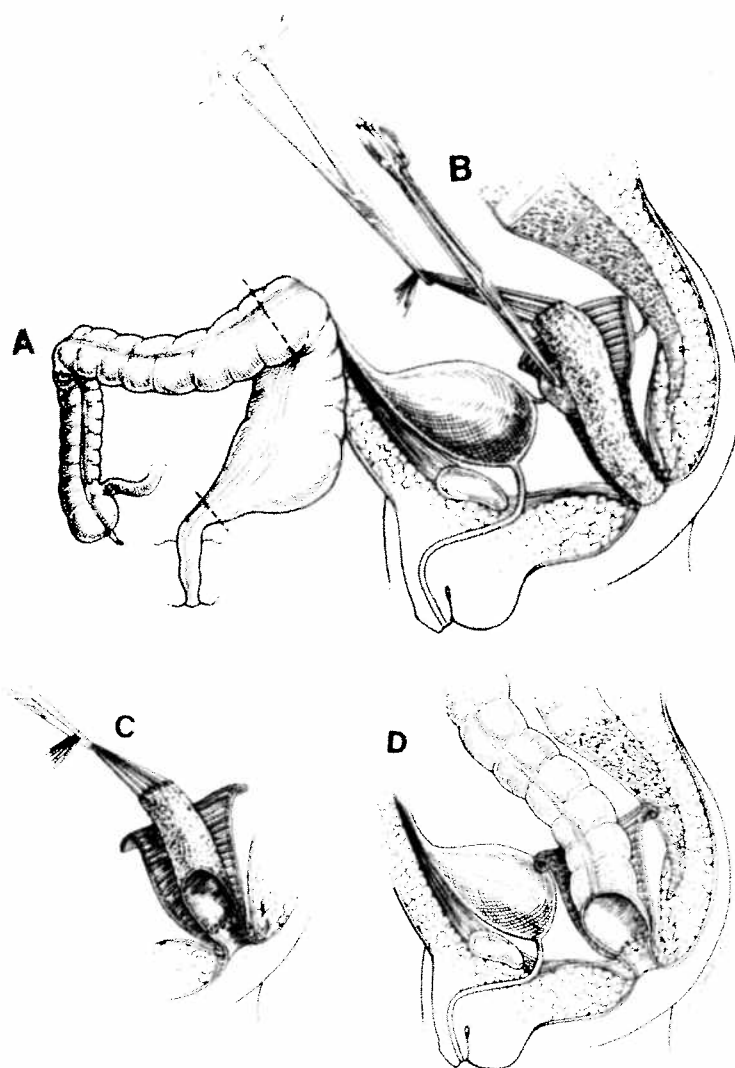


Figure 24.3. Soave technique. A: Resection of dilated colon plus intraperitoneal aganglionic segment. B: Endorectal intrapelvic dissection. C: Resection of the mucosal aganglionic segment down to the pectinate line. D: Pull-through of normal ganglionic bowel through the muscle cuff and anastomosis 1 cm above the pectinate line. From Peña A. Surgical treatment of Hirschsprung's disease. In: Wexner SD, Bartolo DCC, eds. Constipation: Etiology, Evaluation and Management. New York: Butterworth-Heinemann, 1995:168-175, reproduced by permission of Edward Arnold.

and the anal canal. This operation was modified by Boley,¹¹ who proposed a primary anastomosis, avoiding the second procedure.

Laparoscopic-Assisted Procedures

Laparoscopic-assisted techniques have been used in the management of Hirschsprung's disease.¹³⁻¹⁶ The purpose of this technology is to be less invasive in children and substitute a formal laparotomy with a minimally invasive technique that helps the patient to suffer less

postoperative pain and leads to a smoother recovery and earlier discharge. Laparoscopy has been useful in the management of these patients. The surgeons still can use the technique of their preference (Swenson, Duhamel, or Soave) but can make the procedure less invasive by adding a laparoscopic portion rather than a laparotomy. Long-term results of adding a laparoscopic approach to these techniques are still pending. We believe, however, that laparoscopy will not have any negative impact on the results. Therefore, we favor the use of this technology when available.

Figure 24.4. La Torre's. a: Pulling the rectal line. b: Multiple rectal mucosa. c: Full-thickness rectum after and beyond the ganglionic bowel above the pec

Transanal Approach

More recently, De La Torre and Ortega¹² created a simple but ingenious and original way to treat this condition. They demonstrated first in animals and then in humans that the rectosigmoid can be resected in a purely transanal fashion. The resection is performed and the aganglionic segment is simultaneously pulled down through the anus. Interestingly, in the most common type of Hirschsprung's disease (the so-called classic type), the entire aganglionic segment can be transanally resected and

the normoganglionic colon can be anastomosed to the anal canal transanally, avoiding any kind of laparotomy or laparoscopy. Fortunately, the so-called classic form of Hirschsprung's represents approximately 80% of the cases, which gives extra value to this ingenious technique. The transanal approach has been rapidly adopted, and larger series of cases have been reported.^{66,67}

The patient is placed in lithotomy position or alternatively can be placed in a prone position with the pelvis elevated. A special retractor (Lone Star, Houston, Texas) is used to expose the anal canal (Fig. 24.4A). The great advantage of this

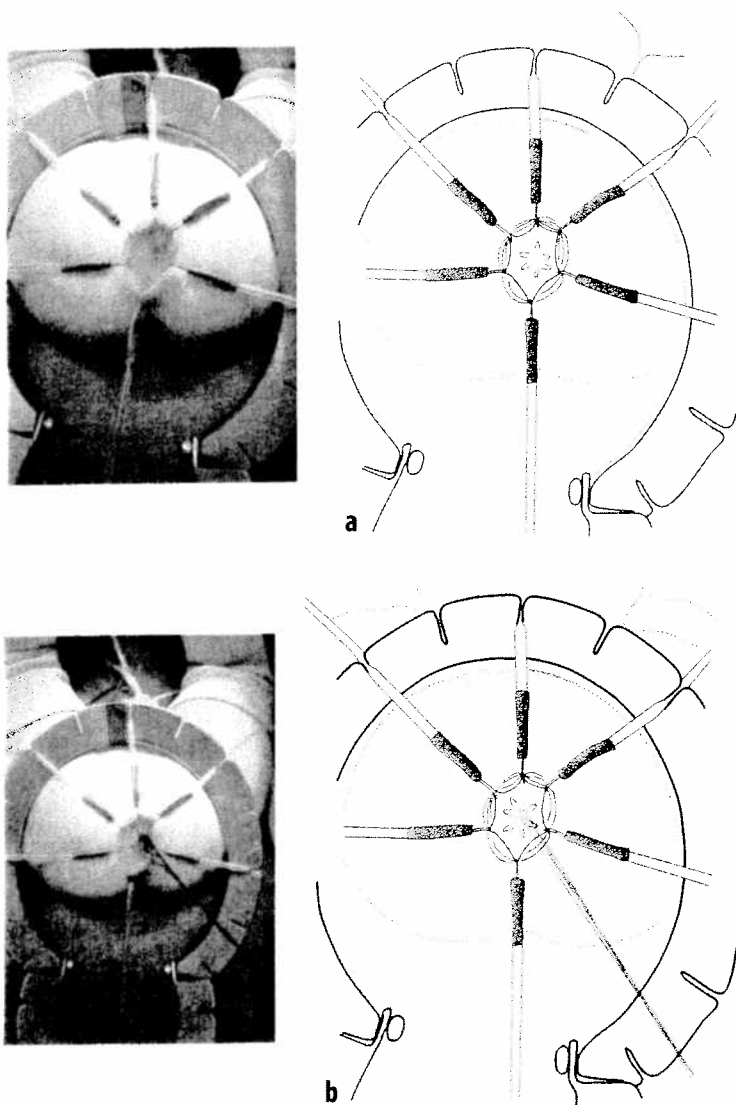


Figure 24.4. Transanal technique (De La Torre). a: "Lone star" retractor exposing the rectal mucosa and pectinate line. b: Multiple silk sutures lifting the rectal mucosa above the pectinate line. c: Full-thickness dissection of the rectum after the peritoneal reflection and beyond. d: Anastomosis of normal ganglionic bowel to the rectum 1 cm above the pectinate line.

nique. A:
colon plus
segment. B:
ection. C:
ganglionic
ate line. D:
ganglionic
cuff and
pectinate
eatment of
SD, Bartolo
Evaluation
tterworth-
roduced by

oother
py has
tients.
f their
e) but
dding
otomy.
scopic
nding.
ill not
There-
when

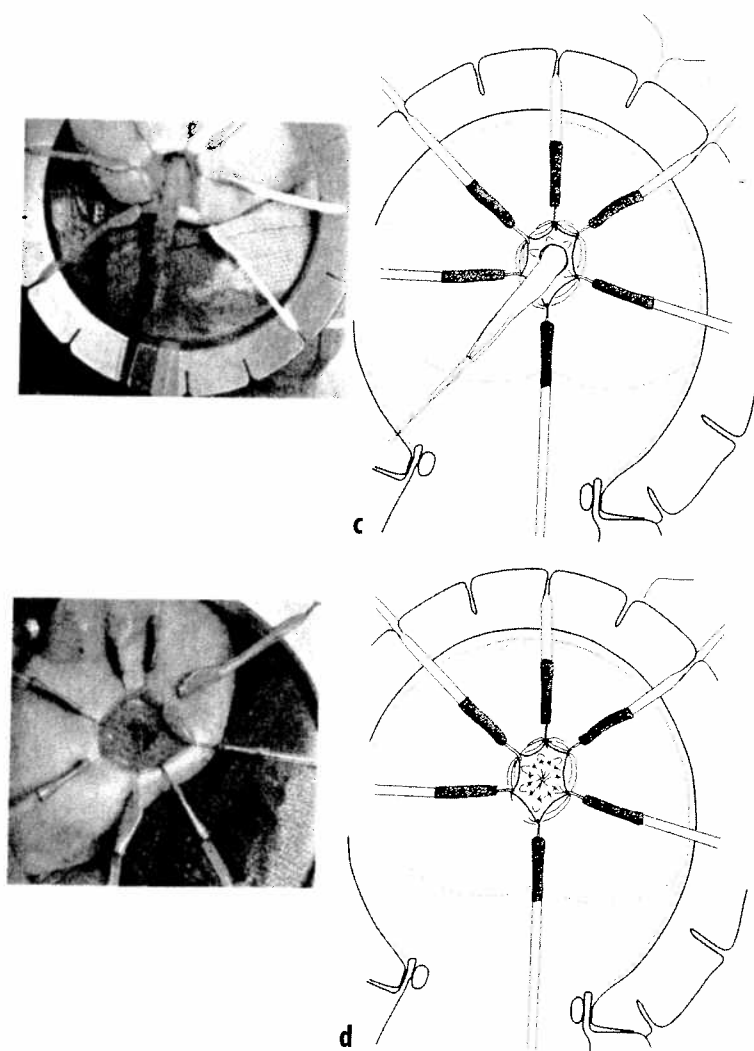


Figure 24.4. Continued

retractor is that it can dilate the anus in a symmetric circumferential fashion to very clearly expose the anal canal. Multiple 6-0 silk sutures are placed, incorporating the rectal mucosa above the anal canal in order to exert the uniform traction that is very important to perform an efficient and neat dissection of the rectum above the pectinate line (Fig. 24.4B). The original De La Torre technique is an endorectal technique performed from below. At our institution, we have been using a transanal full-thickness dissection, or a transanal Swenson procedure. Both ways are equally successful and can be done depending on the experience of the operator. While applying

uniform traction to the multiple 6-0 sutures, a circumferential dissection is performed either submucosally or full-thickness, dividing and cauterizing the extrinsic blood supply of the rectum. By performing this procedure, length is gained in the dissection and, surprisingly, the peritoneal reflection can be reached very rapidly (Fig. 24.4C). As the dissection progresses, one can take full-thickness biopsies.

We advise taking full-thickness biopsies every 4 cm during this dissection. The dissection must continue until the normoganglionic bowel is reached. If, at that point, the surgeon perceives that the colon is already normoganglionic but

Surgica

very
secti
color
resec
up to
desce
that,
rathe
one
lapar
We
mosi
long-
moga
colon
receiv
initia

Com

Opera
diseas
vental
cation
retrac
These
ing a

Fecal

Fecal
proble
Hirsch
nence
the ba
this pr
used. I
canal.
above
be pr
nique
diseas
gastro
nism.
incont
in who
rectum
been d

Dehisc

Dehisc
sequer

very dilated, it is mandatory to continue the dissection until normoganglionic and nondilated colon is reached. One can usually dissect and resect comfortably and safely the rectosigmoid up to the junction of the sigmoid with the descending colon. Endeavoring to go higher than that, even when feasible, makes the procedure rather risky and uncomfortable. At that point, one can continue laparoscopically or by laparotomy.

We routinely perform an end-to-end anastomosis with two layers of interrupted 6-0 long-term absorbable sutures between the normoganglionic, nondistended portion of the colon and the anal canal (Fig. 24.4D). The patient receives parenteral nutrition, and oral feeding is initiated 2 to 4 days after the operation.

Complications

Operative complications in Hirschsprung's disease can be divided into two categories: preventable and unpreventable. Preventable complications include fecal incontinence, dehiscence, retraction, fistula formation, and constipation. These complications can be avoided by observing a meticulous technique.

Fecal Incontinence

Fecal incontinence is still a relatively frequent problem observed in patients operated on for Hirschsprung's disease. We believe that incontinence occurs mainly when the surgeon violates the basic principles applicable to the repair of this problem regardless of the type of technique used. Basically, it consists of damaging the anal canal. The crucial area extending from 1 cm above the pectinate line down to the skin must be preserved, regardless of the surgical technique used in the treatment of Hirschsprung's disease. It contains the most sensitive area of the gastrointestinal tract and the sphincter mechanism. We have seen patients suffering from fecal incontinence operated on at other institutions in whom careful examination of the anus and rectum demonstrates often that this area has been damaged.

Dehiscence and Retraction

Dehiscence and retraction usually occur as a consequence of a deficient technique in the manage-

ment of the blood supply of the normoganglionic bowel. It is very important to carefully observe the blood supply of the colon before making a decision to ligate a branch of the inferior mesenteric, middle colic, or ileocolic vessels, to be sure that the segment to be pulled down still receives adequate blood supply through the arcades of the colonic vessels. The pulled-through colon must lie in its position in a tension-free manner.

Constipation

Constipation occurs mainly in patients in whom normoganglionic but dilated colon has been pulled down. We have learned through the years that a very dilated piece of colon is almost as bad as an aganglionic segment. There is evidence that abnormally dilated portions of any hollow viscus loses its peristalsis. Therefore, regardless of the technique that the surgeon uses, it is imperative to pull down a normoganglionic nondilated part of the colon. However, there must be as yet undefined and unknown factors responsible for the hypomotility observed in normoganglionic colon, since many patients still suffer from postoperative constipation, in spite of the surgeon's pulling down a nondilated portion of the colon.

Unpreventable Complications

Enterocolitis is the most feared, mysterious, unpreventable, and unpredictable complication seen in Hirschsprung's disease. Some surgeons claim that they do not see enterocolitis in their patients. One can only suspect that this is perhaps because they do not look for it. Perhaps they only think of enterocolitis when they see an extremely sick child. We always try to detect these cases very early by taking x-ray films very early postoperatively. One can see varying degrees of dilatation of the colon as well as irregularities in the bowel mucosa indicating that the patient is at risk for developing enterocolitis. We treat these patients with rectal irrigations and metronidazole by mouth and sometimes by rectum. A combination of these measures helps avoid the full picture of enterocolitis. We are unaware of any specific ways to prevent enterocolitis. Besides the medical treatment, consisting of the use of irrigations and metronidazole, some surgeons use myectomies or anal

es, a
ther
cau-
um.
d in
neal
Fig.
ake

very
must
l is
ives
but

dilatations and claim that these yield good results in the management of enterocolitis.⁶⁸ Other surgeons have reported the use of botulinum toxin injected into the internal sphincter. Results have been good but only for short periods of time.⁶⁹

Results

Mortality, in general, has been reported to be between 0% and 3.3%.^{70,71} Swenson claims that 13% of their patients suffer from temporary soiling and 16% to 27% from postoperative enterocolitis, in 16–27%.^{64,65} Duhamel's advocates reported a 10% complication rate.^{6–8,72} Soave¹⁰ reported a 12% incidence of strictures.

We believe that enterocolitis has been underestimated and underreported. The incidence of this complication in different analyses varies from 10% to 30%.^{33–38}

Results of the transanal approach for Hirschsprung's disease are still considered preliminary due to the lack of long-term follow-up. Early follow-up, however, indicates that the results do not seem to be better or worse than those obtained with previous techniques. The transanal approach, however, has obvious advantages over the other operations because it is the least invasive, including laparoscopy. The main concern with the transanal approach is the possibility of interfering with bowel control due to the stretching of the sphincter mechanism that is required to expose the anal area needed to perform this operation.

Total Colonic Aganglionosis

This particular variant of Hirschsprung's still represents a serious technical challenge. Different treatments have been designed to deal with this condition, but all of them are considered less than ideal in terms of results in quality of life. In 1968, Lester Martin⁷³ described his technique for the treatment of total colonic aganglionosis. Patients with total colonic aganglionosis, in order to fulfill the basic principles of treatment of this condition, would require resection of the entire colon and pull-through of the normoganglionic small bowel anastomosed to the anal canal. As expected, these patients suffer from multiple bowel movements during the day and

night, severe diaper rash, and a tendency to suffer dehydration. To avoid these problems, Martin thought that it could be useful to preserve a significant portion of the aganglionic colon to take advantage of its water absorption capacity and also to create a kind of reservoir that would allow the patient to hold the stool and to decrease the number of daily bowel movements. Martin⁷⁴ proposed preserving the rectosigmoid and sometimes even longer portions of the colon. The normal ganglionic terminal ileum is then pulled down through the presacral space (like the Duhamel technique), and anastomosed to the rectum. A long laterolateral anastomosis is created between the terminal ileum and the rectosigmoid; those patients frequently suffer from abdominal distention and bouts of enterocolitis. In retrospect, we know that the small bowel functions well with rapid transit. Stasis in the small bowel produces an inflammatory process that results not only in lack of absorption of water but also a secretory type of diarrhea and enterocolitis. Many of these patients have to be reoperated on to resect the pouch or patch of aganglionic bowel. After Martin, others attempted modifications to his original procedure. Kimura et al,^{75,76} for instance, created a right colon patch basically following the same principles as Martin. Generally the Martin and Kimura procedures, most of the time, are performed with a protecting ileostomy.

References

1. Hirschsprung H. Stuhltragheit neugeborner in folge von dilatation and hypertrophie des colons. *Jahrb Kinderch* 1987;27:1.
2. Tittel K. Über eine angeborene missbildung des dickdarmes. *Wien Klin Wochenschr* 1901;14:903.
3. Whitehouse ER, Kernohan JW. Myenteric plexus in congenital megacolon. *Arch Intern Med* 1948;82:73.
4. Zuelzer WW, Wilson JL. Functional intestinal obstruction on a congenital neurogenic basis in infancy. *Am J Dis Child* 1948;75:40.
5. Swenson O, Bill AH. Resection of rectum and rectosigmoid with preservation of the sphincter for benign spastic lesions producing megacolon. *Surgery* 1948;24:212.
6. Duhamel B. A new operation for the treatment of Hirschsprung's disease. *Arch Dis Child* 1960;35:38.
7. Duhamel B. Retrorectal and transanal pull-through procedure for the treatment of Hirschsprung's disease. *Dis Colon Rectum* 1964;7:455.
8. Duhamel B. Une nouvelle operation pour le megacolon congenital: l'abaissement retrorectal et trans-anal du

- colon, et son application possible au traitement de quelques autres malformations. *Presse Med* 1956;64:2249.
9. Rehbein F, von Zimmermann VH. Ergebnisse der intraabdominellen Resektion bei der Hirschsprung'schen Krankheit. *Zbl Chir* 1959;84:1744.
10. Soave F. Hirschsprung's disease: a new surgical technique. *Arch Dis Child* 1964;39:116.
11. Boley S. An endorectal pull-through operation with primary anastomosis for Hirschsprung's disease. *Surg Gynecol Obstet* 1968;127:353.
12. De La Torre L, Ortega J. Transanal endorectal pullthrough for Hirschsprung's disease. *J Pediatr Surg* 1998;33:1283.
13. Curran TJ, Raffensperger JG. The feasibility of laparoscopic Swenson pull-through. *J Pediatr Surg* 1994;29:1273.
14. Smith BM, Steiner RB, Lobe TE. Laparoscopic Duhamel pullthrough procedure for Hirschsprung's disease in childhood. *J Laparoendosc Surg* 1994;4:273.
15. Georgeson KE, Fuenfer MM, Hardin WD. Primary laparoscopic pullthrough for Hirschsprung's disease in infants and children. *J Pediatr Surg* 1995;30:1017.
16. Georgeson KE, Cohen RD, Hebra A, et al. Primary laparoscopic assisted endorectal colon pullthrough for Hirschsprung's disease: a new gold standard. *Ann Surg* 1999;229:678.
17. Ikawa H, et al. Acetylcholinesterase and manometry in the diagnosis of the constipated child. *Arch Surg* 1986;121:435.
18. Bodian M. Pathologic aids in the diagnosis and management of Hirschsprung's disease. In: Dyke SD, ed. *Recent Advances in Clinical Pathology*. London: Churchill Livingstone, 1960.
19. Ikawa H, et al. A quantitative study of the acetylcholine in Hirschsprung's disease. *J Pediatr Surg* 1980;15:48.
20. Lake BD, Malone MT, Risdon RA. The use of acetylcholinesterase (AChE) in the diagnosis of Hirschsprung's disease and intestinal neuronal dysplasia. *Pediatr Pathol* 1989;9:351.
21. Lake BD, Puri P, Nixon HH, et al. Hirschsprung's disease: an appraisal of histochemically demonstrated acetylcholinesterase activity in suction rectal biopsy specimens as an aid to diagnosis. *Arch Pathol Lab Med* 1978;102:244.
22. Schofield DE, Devine W, Unis EJ. Acetylcholinesterase-stained suction rectal biopsies in the diagnosis of Hirschsprung's disease. *J Pediatr Gastroenterol Nutr* 1990;11:221.
23. Swenson O, Sherman JO, Fisher JH. Diagnosis of congenital megacolon: an analysis of 501 patients. *J Pediatr Surg* 1973;8:587.
24. Vane D, Grosfeld J. Hirschsprung's disease, experience with the Duhamel operation in 195 cases. *Pediatr Surg Int* 1986;1:95.
25. Ikeda K, et al. Long segment aganglionosis (Hirschsprung disease) in brothers. *Shujutsu* 1968;22:806.
26. Ikeda K, Goto S. Total colonic aganglionosis with or without small bowel involvement: an analysis of 137 patients. *J Pediatr Surg* 1986;21:319.
27. Prevot J, et al. Hirschsprung's disease with total colonic involvement. Therapeutic problems. *Prog Pediatr Surg* 1972;4:63.
28. Ziegler MM, Ross AJ, Bishop HC. Total intestinal aganglionosis: a new technique for prolonged survival. *J Pediatr Surg* 1987;22:82.
29. Neilson IR, Yazbeck S. Ultrashort Hirschsprung's disease: myth or reality. *J Pediatr Surg* 1990;25:1135.
30. Bealer JF, et al. Effect of nitric oxide on the colonic smooth muscle of patients with Hirschsprung's disease. *J Pediatr Surg* 1994;29:1025.
31. Kobayashi H, O'Brian DS, Puri P. Lack of expression of NADPH—diaphorase and neutral cell adhesion molecule (NCAM) in colonic muscle of patients with Hirschsprung's disease. *J Pediatr Surg* 1994;29:301.
32. O'Kelly TJ, et al. Abnormalities of nitric-oxide producing neurons in Hirschsprung's disease: morphology and implications. *J Pediatr Surg* 1994;29:294.
33. Bill JAH, Chapman ND. The enterocolitis of Hirschsprung's disease: its natural history and treatment. *Am J Surg* 1962;103:70.
34. Caneiro P. Enterocolitis in Hirschsprung's disease. *Pediatr Surg Int* 1992;7:356.
35. Elhalaby EA. Enterocolitis associated with Hirschsprung's disease: a clinical-radiological characterization based on 168 patients. *J Pediatr Surg* 1995;30:76.
36. Elhalaby EA, et al. Enterocolitis associated with Hirschsprung's disease: a clinical histopathological correlative study. *J Pediatr Surg* 1995;30:1023.
37. Fujimoto J, Puri P. Persistence of enterocolitis following diversion of fecal stream in Hirschsprung's disease. A study of mucosal defense mechanisms. *Pediatr Surg Int* 1988;3:141.
38. Lifschitz CH, Bloss R. Persistence of colitis in Hirschsprung's disease. *J Pediatr Gastroenterol Nutr* 1985;4:291.
39. Wilson-Storey D, Scobie WG. Impaired gastrointestinal mucosal defense in Hirschsprung's disease: a clue to the pathogenesis of enterocolitis? *J Pediatr Surg* 1989;24:462.
40. Wilson-Storey D, Scobie WG, Raeburn JA. Defective white blood cell function in Hirschsprung's disease: a possible predisposing factor to enterocolitis. *J R Coll Surg Edinb* 1988;33:185.
41. Russell MB, Russell CA, Niebuhr E. An epidemiological study of Hirschsprung's disease and additional anomalies. *Acta Paediatr* 1994;83:68.
42. Spouge D, Baird PA. Hirschsprung's disease in a large birth cohort. *Teratology* 1985;32:171.
43. Orr JD, Scobie WJ. Presentation and incidence of Hirschsprung's disease. *Br Med J* 1983;287:1671.
44. Bielschowsky M, Scholfield G. Studies on the inheritance and neurohistology of megacolon in mice. *Proc Univ Otago Med School* 1960;38:14.
45. Rosenfield NS, et al. Hirschsprung's disease: accuracy of the barium enema examination. *Radiology* 1984;150:393.
46. Smith GH, Cass D. Infantile Hirschsprung's disease is a barium enema useful? *Pediatr Surg Int* 1991;6:318.
47. Taxman TL, Yulish BS, Rothstein FC. How useful is the barium enema in the diagnosis of infantile Hirschsprung's disease? *Am J Dis Child* 1986;140:881.
48. Davies M, Cywes S, Rode H. The manometric evaluation of the rectospincteric reflex in total colonic aganglionosis. *J Pediatr Surg* 1981;16:300.
49. Loening-Baucke V, Pringle KC, Ekwo EE. Anorectal manometry for the exclusion of Hirschsprung's disease in neonates. *J Pediatr Gastroenterol Nutr* 1985;4:596.
50. Loening-Baucke VA. Anorectal manometry: experiences with strain gauge pressure transducers for the

- diagnosis of Hirschsprung's disease. *J Pediatr Surg* 1983;18:595.
51. Meunier P, Marechal JM, Mollard P. Accuracy of the manometric diagnosis of Hirschsprung's disease. *J Pediatr Surg* 1978;13:411.
 52. Tamate S, et al. Manometric diagnosis of Hirschsprung's disease in the neonatal period. *J Pediatr Surg* 1984;19:285.
 53. Yokoyama J, et al. studies on the rectoanal reflex in children and in experimental animals: an evaluation of neuronal control of the rectoanal reflex. *Prog Pediatr Surg* 1989;25:5.
 54. Andrass RJ, Isaacs H, Weitzman JJ. Rectal suction biopsy for the diagnosis of Hirschsprung's disease. *Ann Surg* 1981;193:419.
 55. Athow AC, Filipe MI, Drake DP. Problems and advantages of acetylcholinesterase histochemistry of rectal suction biopsies in the diagnosis of Hirschsprung's disease. *J Pediatr Surg* 1990;25:520.
 56. Challa VR, et al. Histologic diagnosis of Hirschsprung's disease: the value of concurrent hematoxylin and eosin and cholinesterase staining of rectal biopsies. *Am J Clin Pathol* 1987;88:324.
 57. Dobbins WO, Bill AH. Diagnosis of Hirschsprung's disease excluded by rectal suction biopsy. *N Engl J Med* 1965;272:990.
 58. Aldridge RT, Campbell PE. Ganglion cell distribution in the normal rectum and anal canal. A basis for the diagnosis of Hirschsprung's disease by anorectal biopsy. *J Pediatr Surg* 1968;3:475.
 59. Swenson O, Fisher JH, Gherardi GJ. Rectal biopsy in the diagnosis of Hirschsprung's disease. *Surgery* 1959;45:690.
 60. So HB, Schwartz DL, Becher JM, et al. Endorectal pullthrough without preliminary colostomy in patients with Hirschsprung's disease. *J Pediatr Surg* 1980;15:470.
 61. Carcassone M, Morisson LG, Letourneau JN. Primary corrective operation without decompression in infants less than three months of age with Hirschsprung's disease. *J Pediatr Surg* 1982;17:241.
 62. Cass DT. Neonatal one stage repair of Hirschsprung's disease. *Pediatr Surg Int* 1990;5:341.
 63. Cilley RE, et al. Definitive treatment of Hirschsprung's disease in the newborn with a one-stage procedure. *Surgery* 1994;115:551.
 64. Weitzman J. Management of Hirschsprung's disease with the Swenson procedure with emphasis on long-term follow-up. *Pediatr Surg Int* 1986;1:100.
 65. Weitzman JJ, Hanson BA, Brennan LP. Management of Hirschsprung's disease with the Swenson procedure. *J Pediatr Surg* 1972;7:157.
 66. Langer JC, Minkes RK, Mazziotti MV, et al. Transanal one stage Soave procedure for infants with Hirschsprung's disease. *J Pediatr Surg* 1999;34:148.
 67. Langer JC, Durrant AC, de la Torre L, et al. One-stage transanal Soave pullthrough for Hirschsprung's disease. A multi-center experience with 141 children. *Ann Surg* 2003;238:569.
 68. Lynn HB, van Heerden JA. Rectal myectomy in Hirschsprung's disease: a decade of experience. *Arch Surg* 1975;110:991.
 69. Ron Y, Avni Y, Lukovetski A, et al. Botulinum toxin type-A in therapy of patients with anismus. *Dis Colon Rectum* 2001;44:1821.
 70. Kleinhaus S, et al. Hirschsprung's disease—a survey of the members of the surgical section of the American Academy of Pediatrics. *J Pediatr Surg* 1979;14:588.
 71. Rescorla FJ, et al. Hirschsprung's disease. Evaluation of mortality and long-term function in 260 cases. *Arch Surg* 1992;127:934.
 72. Talbert JL, Seashore JH, Ravitch MM. Evaluation of a modified Duhamel operation for correction of Hirschsprung's disease. *Ann Surg* 1974;179:671.
 73. Martin LW. Surgical management of Hirschsprung's disease involving the small intestine. *Arch Surg* 1968;97:183.
 74. Martin L. Surgical management of total aganglionosis. *Ann Surg* 1972;176:343.
 75. Kimura K, Mishijima E, Muraji T. A new surgical approach to extensive aganglionosis. *J Pediatr Surg* 1981;16:840.
 76. Kimura K, et al. Extensive aganglionosis: further experience with the colonic patch graft procedure and long-term results. *J Pediatr Surg* 1988;23:52.

Protocol FOR COLONIC IRRIGATIONS WITH FLAGYL (Metronidazole)

RATIONALE: Patients with Hirschsprung's Disease may commonly suffer from enterocolitis, either before or after corrective surgery. They have an underlying dysmotility of the colon which leads to the stasis of their stool, subsequent bacterial overgrowth and then secretory diarrhea. Sometimes the enterocolitis gives less dramatic symptoms such as failure to thrive and intermittent cramping and abdominal pain.

The treatment of enterocolitis when it is severe enough to warrant inpatient care involves aggressive colonic irrigations, intravenous antibiotics (Metronidazole) and intravenous hydration. Upon discharge, or with a mild case that can be treated on an outpatient basis, Flagyl can be given prophylactically either orally or via colonic irrigations.

We have found that oral Flagyl is poorly tolerated by many children because of its metallic taste and have, therefore, utilized the same dose of Flagyl given in the daily irrigation, and have been found this to be very effective. Its goal is to treat the colonic bacteria causing the enterocolitis, most specifically, Clostridium Difficile. The irrigation overcomes the stasis of the stool and allows for more frequent emptying of the colon.

DOSING: The dosing specifications for irrigant Flagyl are as follows:

500 mg Flagyl (intravenous solution) in 100 ml normal saline solution*

*For infants and children, not > 30 mg/kg/day.

ADMINISTRATION:

Ideally, a patient should be irrigated first with normal saline solution beginning with 10-20ml at a time for a total of 20ml/kg. The rationale is to clean the colon of stool before instilling Flagyl irrigation.

To begin Flagyl irrigations, proceed as follows

- Access the Flagyl solution with a Pentothal pen
- Gently squeeze the bag of Flagyl solution into a non-sterile basin (emesis basin)
- Using a 60 ml catheter tip syringe, draw up 20 ml of Flagyl solution at a time.
- Gently insert appropriately-size lubricated silicone catheter into the rectum, approximately six (6) inches (size of the catheter is dependent on the size of the child).
- Place the catheter tip syringe into the end of the silicone catheter and inject 20 ml of Flagyl solution into the rectum
- Disconnect syringe from the end of the catheter; allow irrigant to drip into an empty emesis basin which will be used for your discarded Flagyl solution
- Repeat this process until the total amount of Flagyl solution ordered as been instilled

***NOTE:** It will be important in between instillations of the 20 ml of Flagyl solution to allow the solution to drain from the catheter into the emesis basin with the discarded solution. For example, if you are giving 100 ml of Flagyl solution, you should have the same amount of solution plus stool in the basin.



Increased heritability of certain types of anorectal malformations

Richard A. Falcone Jr^{a,d,e,*}, Marc A. Levitt^{a,d,e}, Alberto Peña^{a,d,e}, Michael Bates^{b,c,d,f}

^aDivision of Pediatric and Thoracic Surgery, Cincinnati Children's Hospital Medical Center, Cincinnati, OH 45229-3039, USA

^bDivision of Gastroenterology, Hepatology and Nutrition, Cincinnati Children's Hospital Medical Center, Cincinnati, OH 45229-3039, USA

^cDivision of Developmental Biology, Cincinnati Children's Hospital Medical Center, Cincinnati, OH 45229-3039, USA

^dColorectal Center for Children, Cincinnati Children's Hospital Medical Center, Cincinnati, OH 45229-3039, USA

^eDepartment of Surgery, University of Cincinnati College of Medicine, Cincinnati, OH 45229, USA

^fDepartment of Pediatrics, University of Cincinnati College of Medicine, Cincinnati, OH 45229, USA

Index words:

Anorectal malformation;
Imperforate anus;
Genetics

Abstract

Purpose: Various lines of evidence point to genetic causes for the diverse spectrum of anorectal malformations (ARMs); we therefore studied patterns of heritability in a large case series.

Methods: We searched our ARM database for all patients having family members with congenital anomalies. This group was analyzed to determine the type of ARM and the specific anomalies in affected family members.

Results: Thirty-nine of 1606 patients (2.4%) had a family member with a congenital anomaly. The associated non-ARM anomalies included sacral masses and gynecologic, hematologic, esophageal, duodenal, renal, and spinal anomalies. Of these, 24 patients (1.4%) had 1 or more family members with an ARM. Among females with a positive family history, 73% of patients had either a vestibular or perineal fistula, compared with only 36% in patients without a family history ($P = .0004$). Among males, 35% had perineal fistulas compared with only 10% of those without affected family members ($P = .0051$).

Conclusions: A positive family history in 1.4% is supportive of a strong genetic component to ARM. The risk of having an affected family member is significantly increased in the presence of a vestibular or perineal fistula. These new data allow for more informed counseling of families with an ARM and support the need for further genetic studies.

© 2007 Elsevier Inc. All rights reserved.

Presented at the 37th Annual Meeting of the American Pediatric Surgical Association, May 20–24, 2006, Hilton Head, SC.

* Corresponding author. Division of Pediatric and Thoracic Surgery, Cincinnati Children's Hospital Medical Center, Cincinnati, OH 45229-3039, USA.

E-mail address: richard.falcone@cchmc.org (R.A. Falcone).

Anorectal malformations (ARMs) represent a spectrum of abnormalities ranging from mild anal anomalies to complex cloacal malformations. The etiology of such malformations remains unclear and is likely multifactorial. There are however reasons to believe that there is a genetic component. As early as the 1950s, it was recognized that

Table 1 Patients with more than 1 family member with a congenital anomaly

ARM in patient	Relationship of family member	Anomaly in family member
Vestibular fistula	Aunt	Vaginal atresia
	Uncle	Esophageal atresia
Vaginal fistula	Father	ARM
	Brother	ARM
	Uncle	Sacral tumor
Perineal fistula	Uncle	Currarino's syndrome
	Grandmother	Currarino's syndrome
Urethral fistula	Mother	ARM
	Uncle	ARM
Bladder fistula	Brother	ARM/Fanconi's anemia
	Brother	Aplastic anemia
Urethral fistula	Mother	ARM
	Brother	ARM
	Uncle	ARM

there was an increased risk for a sibling of a patient with ARM to be born with a malformation, as much as 1 in 100, compared with the incidence of about 1 in 5000 in the general population [1]. Since that time, there have been many reports describing families with 2 or more affected members and associations of ARMs with multisystem syndromes [2,3]. In particular, mutations in specific genes encoding transcription factors have been described in patients having Townes-Brocks syndrome [4,5], Currarino's syndrome [6,7], and Pallister-Hall syndrome [8,9], each of which have autosomal dominant modes of inheritance. In addition, it has been found that there is not only an increased incidence of ARM in patients with trisomy 21 (Down's syndrome), but that 95% of patients with trisomy 21 and ARM have imperforate anus without fistula, compared with only 5% of all patients with ARM [10]. Based on this evidence, it is likely that the mutation of a variety of different genes can result in ARM, or that the etiology of ARM is multigenic [2].

Despite apparent genetic associations, the lack of precise data makes counseling parents about the risk of ARM in future children or future generations challenging. Given the known association in trisomy 21 with a specific anomaly, we hypothesized that there would be different familial associations based on the type of ARM. In addition, we hypothesized that there would be an increased association with pelvic or genitourinary non-ARM congenital anomalies in family members secondary to gene abnormalities affecting development.

1. Methods

Our extensive database of patients with ARM was searched to identify patients in whom family members had ARMs or other congenital anomalies identified. Specific information regarding the type of ARM and associated

anomalies was evaluated for each identified patient. Review of patient charts was used for all identified patients to supplement data from the database as needed. In addition, information about the anomaly identified and the relationship of the family member was reviewed. Patients were then divided into groups based on the classification of their anorectal anatomy [11] and analysis of associated anomalies performed.

Data analysis was performed using SAS v 9.1 (SAS Institute, Inc, Cary, NC). Comparisons were performed using Fisher's Exact test and relative risks calculated. Results were considered significant with $P < .05$.

This study was reviewed by the international review board and determined to be exempt.

2. Results

A total of 1606 patients with ARM were identified in our database. Of this group, 39 (2.4%) had at least 1 family member with a congenital anomaly. Six (15%) of these 39 patients had more than 1 affected family member (Table 1). Associated non-ARM anomalies within the index patients and family members were primarily genitourinary or pelvic anomalies (28 [72%] of 39 anomalies) (Table 2). The genitourinary or pelvic anomalies ranged from simple

Table 2 Associated non-ARM anomalies

Index patient (n = 39)	Family members (n = 46)
Cardiac (6)	Cardiac (0)
Ventricular septal defect (2)	
Atrial septal defect (4)	
Sacral mass (4)	Sacral mass (4)
	Currarino's syndrome (3)
Gastrointestinal (9)	Gastrointestinal (2)
Duodenal atresia	Duodenal atresia
Esophageal atresia	Esophageal atresia
Omphalocele (2)	
Malrotation (2)	
Duplicated appendix	
Ileal atresia	
Colonic atresia	
Genitourinary (16)	Genitourinary (4)
Duplicated müllerian structures (6)	Duplicated Müllerian structures
Bifid scrotum (3)	Bicornate uterus
Hypospadias (2)	Vaginal atresia
Single kidney (2)	Single kidney
UPJ obstruction	
Undescended testis	
Hematologic (0)	Hematologic (2)
	Fanconi's anemia
	Aplastic anemia
	Other (2)
	Meningocele
	Down's syndrome

UPJ, ureteral pelvic junction.

Table 3 Classification of ARM in those with affected family members compared with the entire series

Classification of ARM	% of those with affected family member	% of the entire series
Females		
Vestibular/perineal fistula	74*	37
Cloaca	18*	47
Atresia	5	0.5
Vaginal fistula	5	1
Males		
Bulbar fistula	35	27
Perineal fistula	35*	11
Bladder fistula	12	12
Prostatic fistula	6*	31
Anal stenosis	6	0.3

* $P < .05$ compared with the percentage of the entire series.

bicornate uterus and sacral lipoma to vaginal atresia and presacral teratomas.

A total of 24 (1.4%) of the 1606 patients had at least 1 family member with an ARM. The male to female ratio in this group was 1:2.4, compared with a ratio of 1:1.1 for the entire series. There were 14 siblings with ARM, of which 3 were twins.

The types of ARMs seen in those with affected family members differed from those observed in the series as a whole (Table 3). In males with a perineal fistula, there was a 7% chance (6 of 82 patients) of having an affected family member (relative risk, 3.45; 95% confidence interval, 1.75–6.79). Among females with a perineal or vestibular fistula, there was a 5% chance (16 of 312 patients) of having an affected family member (relative risk, 2.02; 95% confidence interval, 1.54–2.66).

Of the patients with a perineal or vestibular fistula, 3.0% (12/394) had a family member with an ARM and 5.6% (22 of 394) had a family member with some congenital anomaly. Given the estimated incidence of ARM in 1 in 5000 live births, these numbers place a relative of a child with a perineal or vestibular fistula at nearly 150 times increased chance of being affected.

In contrast, there was a reduction in relative risk of having an affected family member for patients with a cloaca (0.38, $P < .05$) or prostatic (0.18, $P < .05$) fistula; these anomalies were less common in patients with affected family members.

3. Discussion

We studied the familial incidence of ARM in the largest reported case series. Among all of the patients in the series, we found a 1.4% incidence of a positive family history for ARM, supporting the previous estimate of approximately 1% [1]. To date, no associations between specific types of ARMs and positive family history have previously been reported. Our analysis of this large case series, however, has revealed

an increased association of specific types of ARM, namely, perineal or vestibular fistulas, with affected family members. Thus, patients with these types of ARMs have 2 to 3 times higher chance of having a family member with an ARM. Both the 1.4% overall incidence and 3% incidence in patients with perineal or vestibular fistula are significantly higher than would be predicted based on an overall incidence of ARM of 1:5000 (0.02%). These results strongly support a genetic component to the etiology of ARM. In addition, these findings are supported by previous findings of the EUROCAT working group, which reported epidemiologic differences among the various types of anal anomalies suggesting different embryological or genetic origins [12].

Before this study, parents of a child with an ARM or a family member with an ARM received counseling only regarding the approximately 1% chance of having another child with a malformation based on literature from the 1950s that included little detail [1]. Our study provides a first step in giving physicians information on risk based on specific classifications of ARM. Thus, based on our findings, parents of children with perineal or vestibular fistulas can now be told that there is a 3% chance of another family member being affected. In addition, parents of boys born with a perineal fistula or girls born with a perineal/vestibular fistula can now be counseled that there is a 7% or 5% chance, respectively, of having a family member with a congenital anomaly. Furthermore, in our series, there was less family transmission among patients with either cloacas or prostatic fistulas.

One potential difficulty with our study is that, despite its size, it is not population based, so there is the potential for bias based on our referral pattern and a disproportionate number of complex ARMs in our series. It is possible, given that most of the patients in this series were referred from other centers, that we actually see a slightly higher rate of those with affected family members. These families may in fact seek evaluation at our center because of their prior knowledge of ARM and treatment options. Despite these potential limitations, it is unlikely that these referral patterns have a significant enough impact to diminish the patterns observed. In the future, it would be desirable to gather similar data by performing a multiinstitutional or population-based review of patients with ARM. Such a review would likely be affected by difficulties in ascertaining the type of ARM and obtaining details of family history, information that has been actively sought and recorded in our database since its inception.

Adding support to the likelihood that ARMs represent genetic “inborn errors of development” is our new finding that 15 (0.9%) of 1606 patients with ARM have a family member with a non-ARM congenital anomaly. Of these, we found that more than 50% were genitourinary or pelvic. Based on these numbers, it would seem prudent to have a higher degree of suspicion for such anomalies in families in which a member has an ARM. However, given that the number and severity of such anomalies in our series were

fairly small, it is hard to justify routine screening of all family members. It is important however to realize that, in 4 patients, the anomalies identified were sacral masses having potential malignant or neurologic complications that would likely be able to be identified by a simple rectal examination or suggested by a plain x-ray of the pelvis.

Animal studies also point to genetic causes of ARM. For example, lines of mice [13,14] and pigs [15] with inherited ARMs have been described, and there is recent evidence of increased incidence of ARMs in certain breeds of dogs [16]. Although, to date, the specific mutations have not been studied in the mouse lines, a recent report has identified several regions of the pig genome that are linked to the ARM phenotype [17]. Furthermore, gene targeting in mice has demonstrated the importance of a number of genes, singly or in combination, for normal hindgut development. In this way, it is likely that ARM is similar to the prototypical congenital anomaly of the digestive system, Hirschsprung's disease (congenital colonic aganglionosis), which also affects about 1 in 5000 live births [18-20].

Prior descriptions of affected families, multisystem syndromes including ARM, studies of knockout mice, and this report all point to the role of genetic factors and even specific genes in development and malformation of the distal hindgut. To date, these findings have not been translated into studies of humans with ARM. In the future, it will be essential to identify specific genes associated with human ARM. To accomplish this task, it will be necessary to develop a patient registry and genomic DNA repository for patients with ARM. It will then be necessary to test candidate genes based on previous studies with knockout mice against genes of families with multiple affected members. In addition, linkage analysis will need to be performed to link familial ARM to specific loci on the human chromosome. A need to advance research in this area has been put forward by the World Congress of Pediatric Gastroenterology, Hepatology and Nutrition [21]. Such studies in the past have been limited by the rarity of the malformation with the care of such patients not localized to individual centers. The continued use of large case series and multicenter registries will be essential to conducting further studies to better understand the genetics of these malformations.

Acknowledgments

We thank George Rodriguez and Emily Loudon for their assistance with the ARM database and on the preparation of the manuscript.

References

- [1] Anderson RC, Reed SC. The likelihood of recurrence of congenital malformations. *J Lancet* 1954;74(5):175-6.

- [2] Boockvar GR, Donnai D. Anorectal malformation: familial aspects and associated anomalies. *Arch Dis Child* 1987;62(6):576-9.
- [3] Kubiak R, Upadhyay V. Isolated imperforate anus in monozygotic twins: case report and implications. *J Pediatr Surg* 2005;40(3):E1-E4.
- [4] Kohlhaas J, Wischermann A, Reichenbach H, et al. Mutations in the *SALL1* putative transcription factor gene cause Townes-Brocks syndrome. *Nat Genet* 1998;18(1):81-3.
- [5] Townes PL, Brocks ER. Hereditary syndrome of imperforate anus with hand, foot, and ear anomalies. *J Pediatr* 1972;81(2):321-6.
- [6] Currarino G, Coln D, Votteler T. Triad of anorectal, sacral, and presacral anomalies. *AJR Am J Roentgenol* 1981;137(2):395-8.
- [7] Ross AJ, Ruiz-Perez V, Wang Y, et al. A homeobox gene, *HLXB9*, is the major locus for dominantly inherited sacral agenesis. *Nat Genet* 1998;20(4):358-61.
- [8] Böse J, Grotewold L, Ruther U. Pallister-Hall syndrome phenotype in mice mutant for *Gli3*. *Hum Mol Genet* 2002;11(9):1129-35.
- [9] Hall JG, Pallister PD, Clarren SK, et al. Congenital hypothalamic hamartoblastoma, hypopituitarism, imperforate anus and postaxial polydactyly—a new syndrome? Part I: Clinical, causal, and pathogenetic considerations. *Am J Med Genet* 1980;7(1):47-74.
- [10] Torres R, Levitt MA, Tovilla JM, et al. Anorectal malformations and Down's syndrome. *J Pediatr Surg* 1998;33(2):194-7.
- [11] Peña A. Anorectal malformations. *Semin Pediatr Surg* 1995;4(1):35-47.
- [12] Cuschieri A. Descriptive epidemiology of isolated anal anomalies: a survey of 4.6 million births in Europe. *Am J Med Genet* 2001;103(3):207-15.
- [13] Searle AG. The genetics and morphology of two 'luxoid' mutants in the house mouse. *Genet Res* 1964;5:171-97.
- [14] Kluth D, Lambrecht W, Reich P, et al. SD-mice—an animal model for complex anorectal malformations. *Eur J Pediatr Surg* 1991;1(3):183-8.
- [15] van der Putte SCJ, Neeteson FA. The pathogenesis of hereditary congenital malformations of the anorectum in the pig. *Acta Morphol Neerl Scand* 1984;22(1):17-40.
- [16] Vianna ML, Tobias KM. Atresia ani in the dog: a retrospective study. *J Am Anim Hosp Assoc* 2005;41(5):317-22.
- [17] Cassini P, Montironi A, Botti S, et al. Genetic analysis of anal atresia in pigs: evidence for segregation at two main loci. *Mamm Genome* 2005;16(3):164-70.
- [18] Bates MD. Development of the enteric nervous system. *Clin Perinatol* 2002;29(1):97-114.
- [19] Kapur RP. Hirschsprung disease and other enteric dysganglionoses. *Crit Rev Clin Lab Sci* 1999;36(3):225-73.
- [20] Tam PKH, Garcia-Barcelo M. Molecular genetics of Hirschsprung's disease. *Semin Pediatr Surg* 2004;13(4):236-48.
- [21] Martín MG, Silveira TR, Grand R, et al. Genetics of gastrointestinal and hepatobiliary disorders: Working Group Report of the First World Congress of Pediatric Gastroenterology, Hepatology, and Nutrition. *J Pediatr Gastroenterol Nutr* 2002;35(Suppl 2):S118-27.

Discussion

John Gosche, MD (Jackson, MS): Have you looked at the associated anomalies that we see with imperforate anus, and is there an effect at having multiple anomalies?

Michael Bates, MD, PhD (response): We have not look at that in any great detail, but that is an important question. There is mouse and human data that would suggest particular genes that may be involved in VACTERL-type associations, and so that would be of great interest to us so that we can more confidently go after those genes.

Jacob Langer, MD (Toronto, Ontario, Canada): Most of the ones with family histories that I have seen have had Currarino's triad. How many of yours have that problem?

Michael Bates, MD, PhD (response): That's a good question. I don't recall the exact numbers off the top of my head, but it's not all of the patients, definitely not all the patients in the series.

Albert Dibbins, MD (Portland, ME): I saw a family a number of years ago that we could trace through 3 generations—a man with a perineal fistula who had 2 wives. There were 3 daughters. Each of the 3 daughters had perineal or rectovestibular fistulae, and then 2 of the daughters had children. Both the boys had high imperforate anuses and the girl had a rectovestibular fistula, and by that time, all 3 of these children had renal and ear and radial anomalies, and it seemed as if this was obviously X chromosome connected. As you traced it through generations, it was becoming more severe. Did you see progression like that in your multigeneration families that you had a chance to look at?

Michael Bates, MD, PhD (response): No, we have not. That's an interesting question as to whether there is increased survivability because of improvements in care of patients with multiple anomalies or whether there is something, for example, in an environment that is resulting in a more severe phenotype. That's a very interesting observation.

Alberto Pena, MD (Cincinnati, Ohio): I want to invite all of you, my colleagues, to be more proactive in detecting these familial types because we have seen patients with perineal fistula, and then, when we specifically ask the mother, she says I think have the same defect. Many ladies are walking around with the same defect, except that nobody discussed it. And then the grandmother says, oh, my gynecologist also told me that I have something like that. There is another group of patients, the so-called Currarino, where we expect a big presacral mass, but sometimes in every baby that we have—we have families where the baby had a perineal fistula and then we order AP x-ray films of the sacrum and find little defects that represent a small presacral mass and sometimes you find the entire family with that small presacral mass. We suspect that this is much more common than we suspected, but we have to look for those associations. Thank you very much.

Michael Bates, MD, PhD (response): Thank you for that comment. One aspect of the paper that I didn't present in the interest of time that is in the abstract and is in the manuscript is that there are patients who have anorectal malformations who have family members with a variety of caudal lesions, including presacral masses that didn't have an anorectal malformation per se, and there appears to be an increased incidence of that as well, so there may be a variety of phenotypes that eventually we may be able to ascribe to particular gene lesions.

IDIOPATHIC CONSTIPATION

Special Information for Parents

By

Dr. Alberto Peña and Dr. Marc Levitt



Definition

The term “idiopathic constipation” refers to an incapacity to regularly pass stool and is of an unknown origin. It is one of the most common defecation disorders in pediatrics. It’s severity varies and can be a very mild problem which can be solved by changes in diet and re-education of the patient. Some children, however, suffer from a very severe disorder which requires high doses of laxatives and occasionally an operation. This information is related to those children who suffer from extremely severe constipation.

Cause and Origin

The term “idiopathic” means that we doctors do not know the origin of this problem. There are many hypotheses, but none of them explains the problem satisfactorily. Many doctors like to believe that everything starts when a child suffers from an episode of mild fecal impaction (stool retention) caused by a defective diet. When the child passes a hard piece of stool, it may provoke pain. The child remembers this and becomes a “stool retainer” to avoid pain. This then starts a chain of events that ends in severe constipation. However, this does not explain the real origin of the problem.

Other doctors put a great deal of

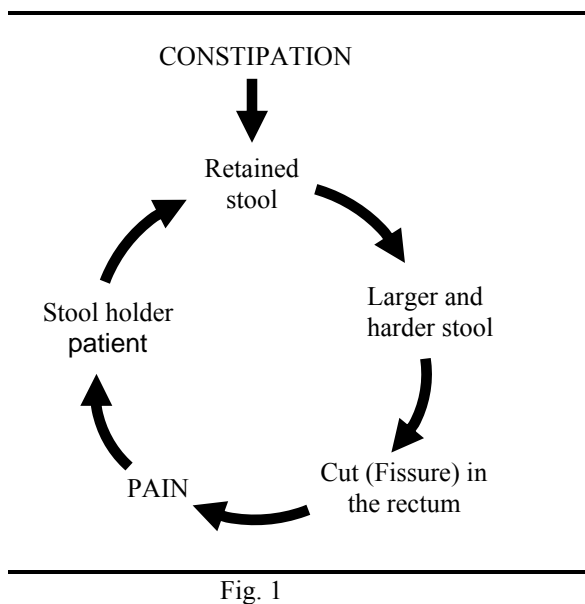
emphasis on the psychological aspects of this condition and believe that a child retains stool due to psychological reasons to manipulate their parents. While most children with constipation eventually do acquire psychological problems, it is hard to believe that severe constipation can be explained on those basis.

Symptoms and Natural History

While we do not know the real nature or origin of this disease, we know the natural history and also the severe secondary consequences that occur when this condition is not treated adequately.

Even when parents state that their children started suffering from constipation at six months to one year of age or at the time of toilet training, a more rigorous investigation usually shows that the patient has suffered from constipation since very early in life. Breast feedings provoke a laxative effect and therefore, most breast fed babies do not show symptoms of constipation until breast feedings stop. Most synthetic baby formulas promote constipation and the initiation of these may mark the beginning of the symptoms of constipation. Constipation may be very mild to start with but eventually, when a child suffers the first episode of fecal impaction (meaning that he goes 1-3 days without passing stool) he forms a rock hard piece of stool inside his rectum which eventually is expelled and this can be a very painful experience. The discomfort can increase, with time the patient retains stool again and eventually, with the use of laxatives, enemas or digital manipulation, the child has a more painful bowel movement. Often, however, a cut in the anus is provoked during the passing of a large, hard piece of stool. This cut, called fissure is reopened each time the child passes more stool. The child has now learned that having a bowel movement is painful and tries

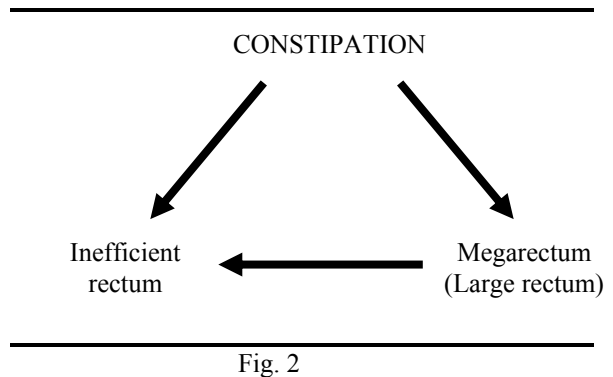
to avoid it. He voluntarily holds the stool which, of course, worsens the problem. The retained stool becomes larger and harder and when it is eventually passed, provokes pain and bleeding. This creates a vicious cycle which makes the problem more difficult to treat. (Fig. 1)



At this point, many parents go to their pediatricians who perform a rectal examination; this is, of course, another painful maneuver which may even reopen a fissure. The child starts focusing his problems on his anus.

When stool stays inside the rectum longer than 24 hours, the rectum enlarges in order to accommodate a large amount of stool. When this problem keeps going for long periods of time, the rectum and colon enlarge enormously and is called “megarectosigmoid.” There is scientific evidence which shows that when a piece of bowel (rectum and sigmoid) becomes very dilated, it loses its’ efficiency to pass stool. The entire intestine in our system has movements called “peristalsis” which pushes the food from the oral side to the anal side. This peristalsis is disturbed when the bowel is

dilated beyond a certain point. In other words constipation provokes megarectosigmoid, which in turn provokes more constipation. Idiopathic constipation is a self-aggravating problem. It is essential for parents to understand this if they expect to help their child. (Fig. 2)



Fecal impaction means that a patient carries a large amount of stool inside his rectum, and is frequently manifested by passing tiny amounts of solid stool inadvertently through the anus. This is also called ENCOPRESIS. This causes constant soiling or smearing of the underwear. When this occurs at school, it becomes a very serious problem which makes the child feel socially unaccepted. At this point, the child develops more serious secondary psychological problems because of rejection by his classmates. What is worse is that the child becomes accustomed to having his underwear always dirty with stool. The smell is very obvious to everyone around him but the child has gotten use to his own odor. The parents must understand that the child is not aware of his own odor.

The natural history of these children, in general, shows that idiopathic constipation is not curable. We have seen many patients to improve but there is little documentation of any real cures. This is very important for parents to understand. Idiopathic constipation in general is manageable but not curable.

Many doctors treat these children diligently for a period of months. They then start decreasing the magnitude of the treatment assuming that the child has changed his habits and is now able to move his bowel every day and is now cured. This provokes recurrence of the initial condition and the parents then become very frustrated.

Parents of children with this condition usually go from doctor to doctor looking for an answer. Different treatments include dietetic changes, psychotherapy, laxatives or other medications and enemas. Often parents are not compliant because they expect a cure and this rarely occurs. When children come to us, they frequently tell us that have already tried every type of laxative and every type of enema and the symptoms persist.

Diagnostic

When a child is seen it is very important that a rectal exam be performed to rule out any organic condition such as an anal narrowing which might require surgical treatment. This is rare. The majority of children who come to see us with constipation do not have any organic condition in their anus. A rectal exam also allows the physician to feel for any stool sitting in the anus. An empty rectum in a patient with severe constipation is frequently a manifestation of another condition called Hirschsprung's disease. This is a condition in which the rectum and part of the colon does not have the normal innervation (absent ganglion cells). The rectum is usually empty and not dilated. The intra-abdominal part of the bowel (sigmoid colon) is very dilated. The narrow portion has no ganglion cells and paradoxically the normal ganglionic bowel is dilated and is usually inside the abdomen.

A study called contrast enema without barium is ordered and usually shows a very dilated colon (megarectosigmoid). In a typical case

of idiopathic constipation, the dilatation of the bowel (megarectosigmoid) extends all the way down to the anal margin. This is completely different from Hirschsprung's disease in which one can see a rather narrow rectum and the megasigmoid is located above inside the abdomen. In between both parts, dilated and non-dilated, is the transition zone. (Figures 3 and 4)

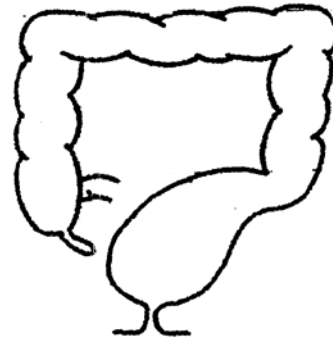


Fig. 3 – Idiopathic constipation

It is also important to rule out other conditions which may provoke constipation such as metabolic disorders (hypothyroidism), spinal disorders, spina bifida, presacral tumors and sacral abnormalities. For this we usually take more specialized tests. The overwhelming great majority of cases with constipation that come to our clinic, however, belong to the category of IDIOPATHIC, meaning that the patients do not have any recognizable problem causing constipation.

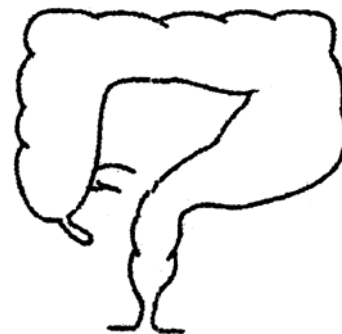

Fig. 4 – Hirschsprungs

Medical Management

The management of these patients requires parents to understand the nature of

this disease. Most people expect to go to the doctor for a prescription of a medicine that will cure their child after 1-2 weeks of treatment. Idiopathic constipation requires prolonged treatment with the hope of reversing the vicious cycle already described making the condition more manageable. By the time these children come to us, they have a significant degree of megarectosigmoid, they have a fissure, and they are afraid of rectal examinations. They suffer from soiling, they are stool retainers, and have severe psychological problems. We believe these children are born with an incapacity to empty the rectum and therefore, they need help to do it. The patient was not born with a severe megarectosigmoid, anal fissure, and being a stool retainer or with psychological problems. All of these are secondary to mismanagement of their constipation. Our goal is to eliminate all these secondary problems. Hopefully, the original incapacity to empty the rectum can be managed either with diet or laxative. It is imperative for parents to understand that these children are not radically cured and that they need some type of supervision for the rest of their lives. When they reach the age of 10 or 12 years and can understand the goals of the treatment, they usually can take care of themselves.

Of course, we do not want to give unnecessary laxatives to these children. In fact, the parents, grandparents and pediatricians are usually against the use of laxatives because they are afraid that the child will become laxative dependent. We believe that these children will not become laxative dependent but rather are laxative dependent already. If the parents do not accept that these children need laxatives everyday, then the child will suffer from worsening constipation. Every additional day that a child has fecal impaction, the problem gets more severe.

The first part of the treatment consists

in disimpacting the colon of the patient. This requires the use of repeated enemas and can take 1-4 days. In severe cases, we may bring the child to the hospital and administer a special solution (Go-lytely) through a nasogastric tube to provoke diarrhea until all the stool finally comes out. In very severe cases, when even the Go-lytely does not clean the child, a trip to the operating room may be necessary to manually disimpact the child under anesthesia.

Once the child is disimpacted, we start management with laxatives. Laxatives are medications that promote bowel motion. Promoting bowel motion against a big plug of solid stool may provoke severe cramps. Often when a child has severe abdominal pain, the parents stop the laxatives. This will again make the management more difficult. It is essential, therefore, to take care of the fecal impaction before we start the treatment with laxatives.

One important basic principle is to recognize that each child needs a different amount of laxative. We determine the amount of laxative that a child needs by trial and error. The amount of laxatives that these children need is frequently much higher than the recommended dosage. This in itself, provokes fear and concern by the parents. There is, however, no alternative. If one does not give the right amount of laxative necessary to avoid fecal impaction, an enema would then have to be given. In general, of course, we try to be as conservative as possible in the management of these children. If a child can be managed with the use of laxative-type foods, then we prefer that method. Unfortunately, laxative-type foods only work for minor types of constipation and not usually on the kind of children we see in our surgical clinic. For the chronic use of laxatives (which most of our patients need) we prefer to use Milk of Magnesia.

Both, the results of the contrast enema and the physical examination of the patient usually give us some idea of the amount of laxative that the patient may need. Based on our experience, we start with an amount that we believe will work. A laxative administered one day is going to show its effect the following day. After the administration of laxative, the child is watched for bowel movements overnight and the rest of the next day. By the end of the day if the child has not voluntarily passed stool it means the amount of laxative that was given was not enough and it then has to be increased. Most importantly, it means that he already has stool from the food that he ingested the day before in his rectum which now has to be removed with an enema to avoid fecal impaction. The management continues with the increased amount of laxatives and is observed for the following 24 hours. Again, if on the following day the child does not have a bowel movement, the laxatives need to be increased and an enema given to remove the stool from the last 24 hours. The parents must continue this treatment until the child finally passes stool. If the child passes stool it means that he does not need an enema and that the desired amount of laxative has already been reached for this special child. The parents should then administer this amount daily to help the child have bowel movements every day. If the child suffers from diarrhea, it may mean that the amount of laxative is too much and it should now be reduced slightly. The final dose is always decided upon by trial and error. (Figure 5)

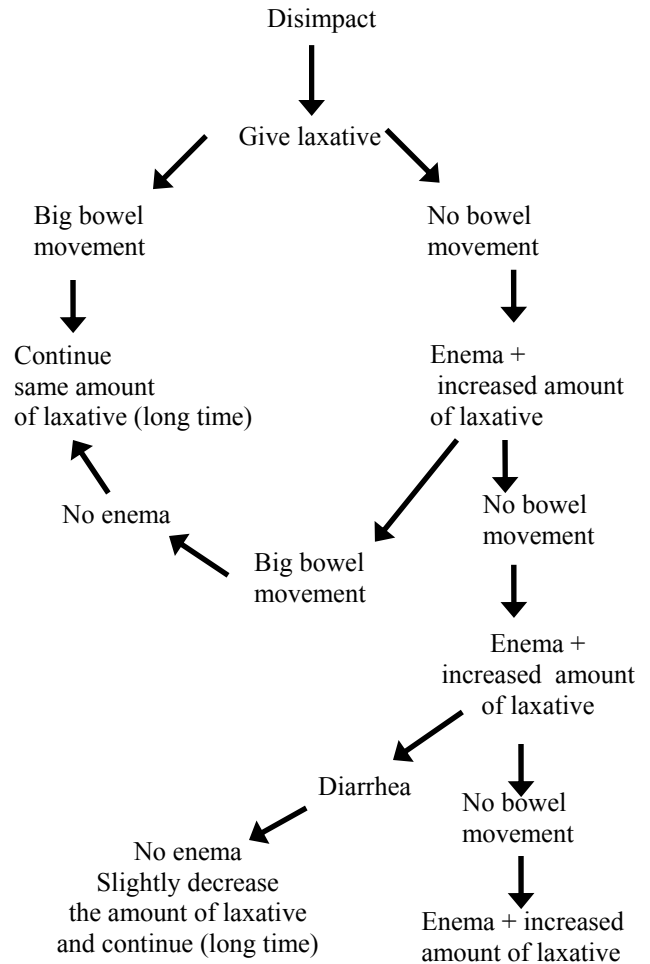


Fig. 5

Once we have determined the dose of laxative that the child needs (which is usually a very large amount) we advise the parents to continue that amount for a long period of time (months). During those months, the parents are encouraged to give laxative-type foods in order to try to decrease the amount of laxative that they are giving so as to provoke bowel movements with the most natural means. Trying to control a constipated patient with just a diet at a pediatric age is rather difficult because sometimes the child is not very consistent in ingesting the types of food that we want him to eat. Realistically, the parents must continue that amount of laxative for a long time. As a matter of fact, as the child

grows, sometimes the amount usually has to be increased.

As the patient grows, our hope is that the child understands and cooperates, he will then begin to ingest a laxative-type of diet every day so to try to avoid the use of laxatives or at least to decrease the dosage.

The parents should not develop false expectations and believe that the child soon will become a normal individual. This is a treacherous condition. The parents try to avoid laxatives and decrease the amount without supervision. Frequently, the patients continue having bowel movements everyday but the parents are unaware of the fact that the child does not really empty his rectum but rather passes small amounts of stool. The patient is soon fecally impacted again and the vicious cycle starts again.

Surgical Options

Patients with very severe intractable constipation are offered an operation. When the parents finally determine the dose of laxative that the child needs, sometimes they find that it is such a large amount of laxative that the child has a hard time taking the medication and sometimes, he vomits. The administration of the laxatives become a serious problem in terms of quality of life. At this point we offer these children a surgical option called sigmoid resection (Figure 6) which alleviates the problem of constipation or at least helps to reduce the amount of laxatives that the patient needs. In a study carried out at our institution we found that over 50% of our patients after surgery, no longer use laxatives to have bowel movements daily. The other 50% significantly reduced the amount of laxatives necessary to have a bowel movement. Other surgeons suggest the use of a procedure called a posterior myotomy

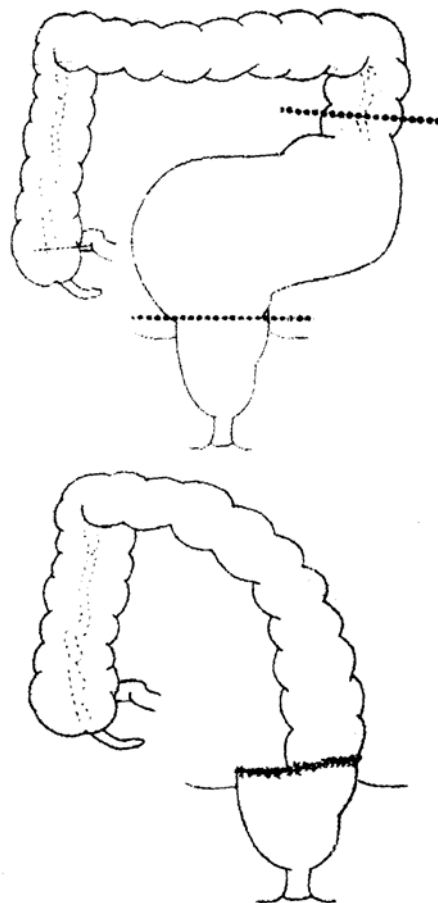


Fig. 6

for the treatment of this condition. That operation is very controversial and the results in the literature are contradictory and therefore, not reliable. We, therefore, do not recommend it.

*Illustrations by G. Rodriguez
November 1997*



Colorectal Center for Children
<http://www.cincinnatichildrens.org/>
(800)344-2462 (513)636-3240 Phone
(513)636 3248 FAX